

# The Role of Transcranial Direct Current Stimulation in Post Stroke Aphasia-A Narrative Review

Duggal AK\*, Sahu D and Garg J

Department of Neurology, Guru Gobind Singh Indraprastha University, India

**\*Corresponding author:** Ashish Kumar Duggal, Professor, Department of Neurology, ABVIMS and Dr RML Hospital, Guru Gobind Singh Indraprastha University, New Delhi, 110001, India, Email: ashishduggal2005@gmail.com

**Received Date:** July 03, 2024; **Published Date:** August 23, 2024

## Abstract

**Introduction:** Post-stroke aphasia is a prevalent and debilitating condition. Studies indicate that at least 1 in 5 stroke patients experience long-term effects of post-stroke aphasia. Speech and language therapy has long been the cornerstone of rehabilitation for these patients. Non-invasive brain stimulation (NIBS) techniques, such as Transcranial Direct Current Stimulation (tDCS), are an upcoming method that has shown promise.

**Methods:** A PUBMED search was done to select papers published for the use of tDCS in post-stroke aphasia. The key search terms used included 'transcranial direct current stimulation' or 'brain polarisation' with 'language', 'aphasia', and 'post-stroke aphasia.' Studies between March 2005 and May 2024 were included.

**Results:** Our search yielded 37 studies of interest. The studies included those conducted on healthy individuals to assess the effects of tDCS and those conducted on patients with post-stroke aphasia. The majority of the studies were conducted in patients with chronic aphasia. Broca's area in the left cerebral hemisphere was the most common stimulation site. Most studies have noted improvement with anodal stimulation of the left cerebral hemisphere, showing benefit in naming nouns but limited improvement in functional conversation. Results of right cerebral hemisphere stimulation conflicted with studies noting improvement with both cathodal and anodal stimulation. There were only a small number of studies on acute and subacute aphasia, and their findings were inconclusive.

**Conclusion:** Transcranial Direct Current Stimulation is a promising tool for post-stroke aphasia rehabilitation and may soon become a cornerstone of aphasia management when used in combination with other rehabilitation techniques. Further research is needed to understand the role of tDCS in treating acute aphasia and to fine-tune the stimulation parameters.

**Keywords:** Post-Stroke Aphasia; Transcranial Direct Current Stimulation; Neuromodulation; Neurorehabilitation

## Abbreviations

NIBS: Non-Invasive Brain Stimulation; tDCS: Transcranial Direct Current Stimulation; TMS: Transcranial Magnetic Stimulation; tACS: Transcranial Alternative Current Stimulation; tRNS: Transcranial Random Noise Stimulation; SLT: Speech and Language Therapies; MEP: Motor-Evoked Potentials; MIT: Melodic Intonation Therapy; ADL: Activities

of Daily Living; fMRI: Functional Magnetic Resonance Imaging.

## Introduction

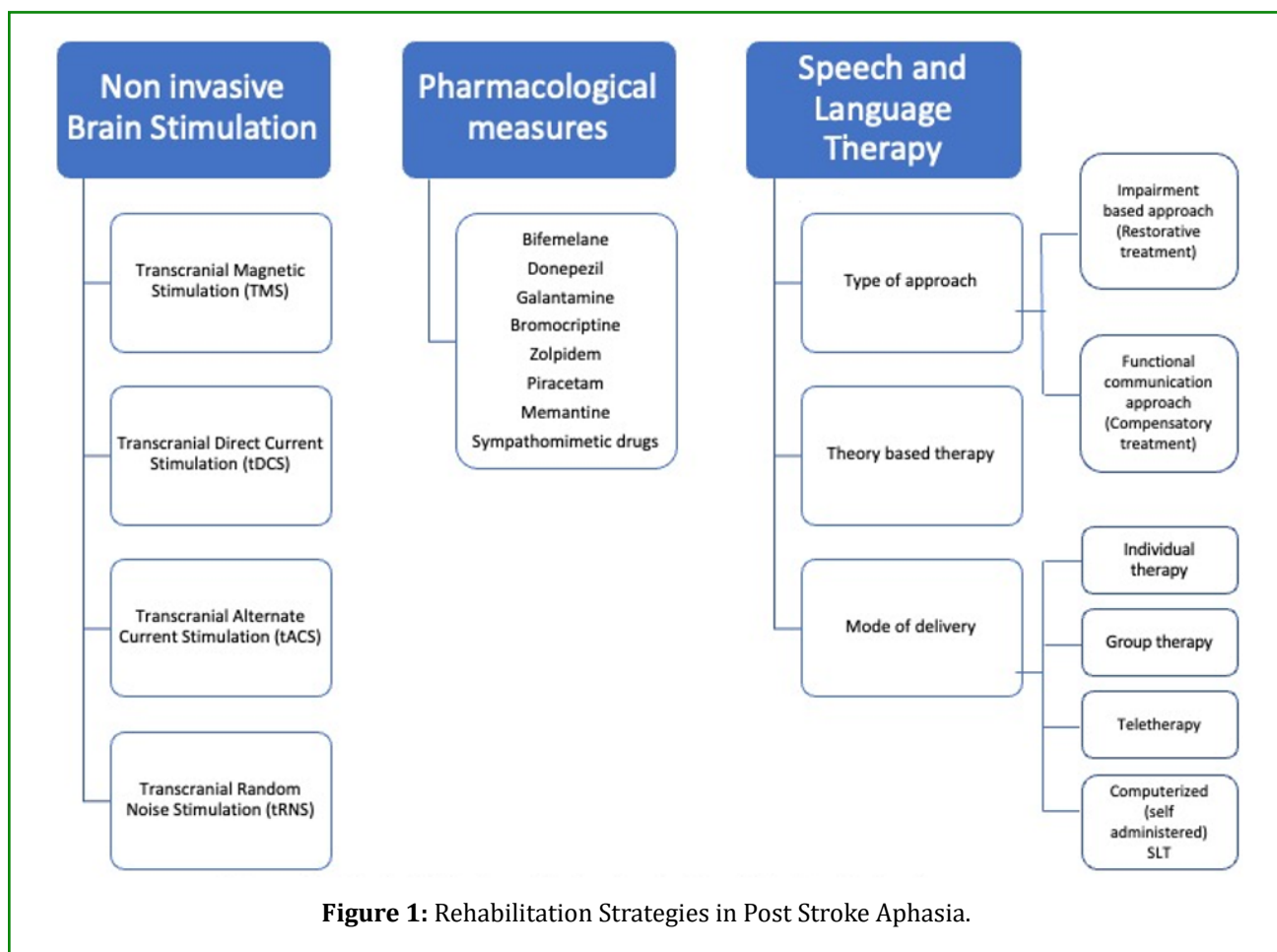
Strokes are one of the most devastating diseases, incurring significant morbidity and mortality. As of 2019, stroke was the second-leading cause of death globally and the third-

leading cause of death and disability combined, with a global incidence estimated to be 12.2 million [1], a prevalence of 101 million [1], DALYs (disability-adjusted life years) lost due to stroke estimated to be 143 million [1], and deaths due to stroke estimated to be 6.55 million [1]. Impairment in communication due to aphasia or dysarthria and motor dysfunction in the form of hemiparesis or hemiplegia are the two most significant morbidities suffered by survivors of stroke. Global estimates of the occurrence of aphasia due to stroke are in the range of 20-40% [2,3]. Indian studies estimate aphasia due to stroke occurs in 21-38% of patients [4]. It has been stated, "One never recovers from aphasia; one recovers with aphasia" [5]. Spontaneous neuroplastic mechanisms and the reorganization of neural networks drive recovery from aphasia [6]. Studies in post-stroke aphasia rehabilitation have focused mainly on the various forms of Speech and Language Therapy. Non-invasive brain Stimulation (NIBS) methods such as Transcranial Magnetic Stimulation (TMS), Transcranial direct current stimulation (tDCS), Transcranial alternate current stimulation (tACS), and Transcranial random noise stimulation (tRNS) have also been used for aphasia rehabilitation. NIBS comprises

stimulation in a target area of the brain by applying an electrical current directly on the scalp or by creating an electrical field with the help of magnetic induction on the scalp. Both TMS and tDCS have been found to modulate motor, sensory, cognitive, and behavioural responses. They can be used in repeated applications for neuromodulation by increasing or decreasing cortical excitability. This review will discuss the role of Transcranial Direct Current Stimulation in post stroke aphasia. We used the PUBMED online database to select papers published from March 2005 to May 2024. Our key search terms were 'tDCS' or 'transcranial direct current stimulation' or 'brain polarisation' combined with 'language' or 'aphasia'.

### Rehabilitative Strategies in Post-Stroke Aphasia

Over the years, various categories of aphasia interventions have been investigated, either separately or in combination. These include Behavioral interventions such as Speech and Language Therapies (SLT) [6,7], Pharmacological therapies [8], and Non-Invasive Brain Stimulation (NIBS) (Figure 1) [9,10].



Speech and language therapy (SLT) is the most common methodology used for aphasia rehabilitation. First described by Paul Broca in his seminal paper in 1865, it remains a cornerstone to this day. The methods used for SLT can be broadly classified as restorative or compensatory [6]. Restorative treatment or impairment-based approaches aim to restore language processing by using the residual linguistic network and targeting the subcomponents of language. They seek to enhance performance on particular language activities, like naming, reading, spelling, word and sentence comprehension, or specific language processes, like lexical semantics, phonology, or syntax. The goal of compensatory treatment/functional communication techniques is to acquire new verbal or nonverbal skills to make up for language deficiencies. One such strategy is to integrate alternate forms of communication with residual language abilities. Functional communication approaches focus on assisting the person in communicating in everyday situations by removing obstacles to communication in the environment, enhancing communication through gestures, drawings, pointing, etc., and providing caregivers with training to improve communication. Multiple medications have been tried for possible beneficial effects in post-stroke aphasia (Figure 1). Since large-scale trials for these medications are not available, none of them are currently approved for use [8].

Non-Invasive Brain Stimulation (NIBS) techniques can be useful for transiently modulating cortical excitability and causing long-term alterations after stimulation. Non-invasive brain stimulation techniques can activate damaged brain areas or suppress areas whose hyperfunction may impair cognitive recovery. rTMS is a type of non-invasive brain stimulation that has been employed for post-stroke aphasia rehabilitation. It is possible to give rTMS at low or high frequencies. High-frequency stimulation is excitatory, while low-frequency stimulation is inhibitory. Usually, in order to promote perilesional left hemisphere activation in both subacute and chronic PSA and to prevent right hemisphere activation during language-related tasks, low-frequency rTMS is frequently delivered to the contralateral right hemisphere [9].

Since 2010, numerous randomized controlled trials have shown the value of rTMS in the rehabilitation of post-stroke aphasia, including subacute, chronic, and post-acute cases [9]. Furthermore, no study discovered that rTMS had a deleterious effect despite the trials being heterogeneous with varying rTMS parameters, stimulation sites, and patient characteristics. A few trials, meanwhile, have not demonstrated any effect; these studies were all related

by the use of low-frequency rTMS, even though the other research components were not comparable. Up until now, meta-analyses of rTMS research have consistently produced positive results, supporting the idea that NIBS may, in fact, be crucial to post-stroke aphasia rehabilitation. Importantly, very few studies have performed an online rTMS with SLT, i.e., applying SLT while undergoing the rTMS session. The reason for this is simple: although synchronous SLT may be more beneficial, rTMS produces a loud clicking noise during administration, which can prove distracting to the patient during SLT.

### **Transcranial Direct Current Stimulation as a Rehabilitative Strategy for Aphasia**

tDCS is a safe, non-invasive, and painless electrical stimulation of the brain that alters cortical excitability by delivering mild electrical currents in the form of direct-current brain polarization, thereby inducing prolonged functional after-effects. tDCS is performed with the help of a battery-driven device [10]. It involves the application of electrodes to the subjects with the passage of a weak electric current between the electrodes. The current isn't strong enough to generate an action potential but can modulate the excitability of the underlying cortical neurons, making them more or less likely to discharge. tDCS offers several advantages. It is non-invasive, portable, reusable, relatively inexpensive, and has minor side effects when used safely. It has a sham mode for single-blinded trials, and its versatility makes it a promising method for rehabilitation, proven to have beneficial effects in patients with Alzheimer's disease, Parkinson's disease, post-stroke motor impairment, and post-stroke cognitive impairment.

### **Effect of tDCS on Language in Normal Subjects**

Few studies have evaluated the effect of tDCS over the frontal and temporal cortex in normal subjects (Table 1). Iyer, et al. found that intensity-dependent improved performance on letter cue-word generation tasks was observed after anodal tDCS over the frontal lobe [11]. On the other hand, verbal fluency slightly decreased after cathodal tDCS. Anodal tDCS over the left dorsolateral prefrontal cortex improves verbal reaction times [12], while cathodal stimulation has no effect. Applying transcranial direct current stimulation (tDCS) over Broca's area can enhance the brain's ability to detect syntactic violations [13]. These studies show that stimulating language areas in healthy individuals can improve various language functions and provide a basis for further research in patients with aphasia.

Author	Stimulation site	Type of Stimulation	Outcomes tested	Results	Comments
Iyer MB, et al. [11]	Left PFC	Anodal Cathodal	Global measures of processing and psychomotor speed, emotion and verbal fluency	Fluency improved with anodal and decreased with cathodal stimulation	Left PFC has a role in verbal fluency
Fertonani A, et al. [12]	Left DLPFC	Anodal Cathodal	Naming performance and verbal reaction times	Improved with Anodal and no effect with cathodal stimulation	Left PFC has a role in verbal fluency
DeVries MH, et al. [13]	Left Broca's Area	Anodal vs Sham	Artificial grammar learning paradigm	Anodal activation of BA improved syntactic violation detection. BA stimulation, may be beneficial in aphasic individuals who have difficulties implementing grammatical rules appropriately.	Broca's area has a role in understanding grammar and implementing grammar appropriately. BA also has a role in verbal fluency.
Liuzzi G, et al. [14]	Left Motor Cortex	Cathodal vs Anodal vs sham	Vocabulary acquisition in a language learning paradigm	Cathodal stimulation reduced success rates in vocabulary acquisition but no such effect in anodal or sham stimulation.	Motor Cortex has a role in acquisition novel action related words.
Floel A, et al. and Fiori V, et al. [15,16]	Left posterior perisylvian area - Wernicke Area	Anodal vs Sham	Learning a new lexicon - speed and accuracy	Anodal stimulation significantly improved word retrieval of newly learned words.	Stimulation of WA can facilitate verbal learning. WA stimulation also improves word retrieval.

**Table 1:** Studies evaluating the effect of tDCS on language function in normal subjects.

### The Rationale for the Use of tDCS in Aphasia

tDCS mechanisms involve synaptic changes (altering synaptic transmission strength) and non-synaptic changes (shifting resting membrane potential). tDCS has a short-term effect on the resting membrane potential and a long-term effect through mechanisms such as long-term potentiation and depression. The long-term effect of tDCS has been shown to be abolished by pharmacological agents acting on the GABAergic, dopaminergic, and cholinergic neurons. tDCS may also have an effect on protein synthesis, calcium neuronal influx, the shape of the cytoskeleton, blood flow, the level of brain oxygenation, and local pH [10,17]. The stimulation can be either anodal or cathodal. In normal individuals, anodal stimulation depolarizes neurons, increasing excitability, while cathodal stimulation has the opposite effect, but the effects may differ between healthy individuals and stroke patients. Suzuki et al. showed that

anodal transcranial direct current stimulation (tDCS) increased the size of motor-evoked potentials (MEP) in both stroke patients and normal subjects [18]. However, cathodal transcranial direct current stimulation (tDCS) enhanced the motor-evoked potential (MEP) in stroke patients when applied to the afflicted hemisphere, but it reduced the MEP in healthy individuals. Transcallosal connections between the two hemispheres allow the hemispheres to inhibit each other mutually. A lesion in the left hemisphere reduces activity in the damaged cortical areas and diminishes the inhibition of the right hemisphere. This, in turn, leads to hyperactivity in the right hemisphere, further decreasing the activity of the left hemispheric areas. So, the rationale for tDCS is to increase the activity of the perilesional cortex (particularly targeting language areas in the left hemisphere (Broca's area, Wernicke's area, or motor cortex), or decrease the inhibitory effect of the contralateral hemisphere (right inferior frontal gyrus).

Anodal tDCS (A-tDCS) is most commonly used in left hemisphere language areas to raise cortical excitability (lower activation threshold) in individuals with chronic aphasia. Even during the early post-stroke period, anodal transcranial direct current stimulation (tDCS) holds potential as a valuable rehabilitation intervention, given the heightened neuroplasticity observed during this phase. It is believed that tDCS has the capability to enhance learning by facilitating long-term potentiation, which is linked to enduring synaptic plasticity. Cathodal stimulation, in contrast, leads to hyperpolarization of the stimulated area, reducing its likelihood of firing. Cathodal tDCS is often applied to the healthy hemisphere to inhibit cross-hemisphere inhibition, allowing greater activation of the injured hemisphere. In dual tDCS, anodal and cathodal stimulation are simultaneously applied.

### Stimulation Parameters used for tDCS in Aphasia

The montage used for tDCS can be either unipolar or bipolar [10]. Unipolar montage comprises one cephalic (over the scalp) and one extracephalic electrode. Bipolar montage requires both electrodes to be placed on the scalp. The placement of the reference electrode is important to the process since electrodes placed too far apart reduce the strength of stimulation applied due to the dissipation of the electric field; electrodes placed too close together may cause involuntary excess current flow under the electrode. The contralateral supraorbital region and contralateral deltoid

are the reference electrode's most commonly used area. Due to the electrodes' size, tDCS can stimulate large cortical areas, albeit with reduced precision. The effects of tDCS are contingent upon factors such as the duration of stimulation, current density, characteristics of the neuronal tissue involved, and the direction of the current flow - whether it moves from the anode to the cathode or vice versa.

The stimulation parameters used for tDCS in aphasia include the intensity of the stimulation delivered, the total duration of stimulation, and periods of ramp up and ramp down, if any. A higher intensity of stimulation delivered could theoretically cause stronger stimulation and guarantee a better outcome. However, intensities exceeding 2mA are rarely used due to the risk of scalp irritation and unintended stimulation. Although optimal parameters remain unknown for the stimulation duration, studies have not used durations more than 30 minutes. It is believed that prolonged stimulation may lead to excessive excitability in the cortex, potentially impeding long-term recovery. The most commonly used parameters in various studies are thus stimulation intensities of less than 2mA and durations of less than 30 minutes each per session.

### Timing of Stimulation and Patient Selection

Most of the studies that have evaluated the role of tDCS in post-stroke aphasia have included patients with chronic aphasia (Tables 2-5).

Study	Participants	Type of Stimulation	Area targeted	Number of sessions	Duration of sessions	Intensity	Speech therapy	Outcomes assessed	Results	Follow up
Hesse S, et al. [19]	5 (3 GA 2 WA)	Anodal stimulation.	Left motor cortex.	30 sessions.	7 minutes	1.5 mA	Yes	Aachener Aphasia test	Anodal tDCS improves performance testing for 4/5 aphasics.	No follow up
Baker JM, et al. [20]	10 (6 AA 4 BA)	Anodal/ Sham.	Left frontal cortex.	5 sessions.	20 minutes	1 mA	Yes	Picture Naming test	Anodal tDCS increases accuracy.	Effects persisted for 1 week after treatment.
Marangolo P, et al. [21]	3(NFA)	Anodal/Sham.	Left inferior frontal cortex.	5 sessions.	20 minutes	1mA	Yes	Syllables, word repetition	tDCS increases accuracy both in anodal and sham conditions, but the effect persists only after anodal condition.	Effects persisted for 2 months after treatment.



Marangolo P, et al. [22]	12 (NFA)	Anodal/Sham.	Broca's area and Wernicke's area.	10 sessions.	20 minutes	1mA	Yes	Informative speech Conversational speech	Anodal tDCS over Broca's area was beneficial.	Effects persisted at 1 month
Volpato C, et al. [23]	8 6 FA 2 NFA	Anodal/Sham.	Broca's area.	14 sessions	20 minutes	2mA	No	Picture Naming test	No significant difference between anodal and sham stimulation.	No follow up
Polanowska KE, et al. [24]	37 13 FA 24 NFA	Anodal/Sham.	Broca's area.	15 sessions.	10 minutes	1mA	Yes	Boston Diagnostic Aphasia Examination	Both groups improved after therapy. No statistically significant difference between the groups.	Improvements persisted at 3 months
Vestito L, et al. [25]	3	Anodal/Sham.	Left frontal region.	10 sessions	20 minutes	1.5mA	Yes	Picture Naming test	Anodal tDCS was beneficial.	Up to 21 weeks. Percentage of correct responses persisted significantly better until the 16th week. Up to the 21st week, the number of correct responses, though no longer significant, was still above the baseline level.
Campana S, et al. [26]	20 NFA	Anodal/Sham.	Left Inferior Frontal Gyrus	10 sessions.	20 minutes	2mA	Yes	Picture description, noun, and verb naming	Improvement in Picture description, noun, and verb naming	No follow up
Wu D, et al. [27]	12 Post subacute. 8 BA, 2 MA, 1 AA, 1 CA	Anodal/Sham.	Left Posterior Perisylvian region.	20 sessions.	20 minutes	1.2mA	-	Picture naming and auditory word picture identification.	Improvement in picture naming and auditory comprehension.	No follow up

Meinzer M, et al. [28]	26, 9 BA, 9 WA, 2 GA, 2 AmA	Anodal/Sham.	Left primary motor cortex	8 sessions.	20 minutes	1 mA	Yes	Naming test	Improvement in naming ability for trained and untrained items.	Effects persisted at 6 months
Branscheidt M, et al. [29]	16 NFA	Anodal/Sham.	Left primary motor cortex.	2 sessions	20 minutes	2mA	No	Lexical decision task	Improvement in overall accuracy	No follow up
Santos MDD, et al. [30]	13, 6 BA, 7 AA	Anodal/Sham.	Left Inferior Frontal Gyrus	1 session	20 minutes	2mA	No	Naming test	No effect on Naming	No follow up
Woodhead ZVJ, et al. [31]	21 (patients with alexia)	Anodal/Sham.	Left Inferior Frontal Gyrus	11 sessions	20 minutes	2mA	Yes	Reading	Improvement in reading ability. No significant changes in the sentence or text reading level.	No follow up
Pestalozzi MI, et al. [32]	14 chronic patients.	Anodal/Sham.	Left DLPFC	1 session	20 minutes	2mA	None	Picture naming, phonemic fluency	Improvement in verbal fluency and in the speed of naming high-frequency words. No improvement in word repetition.	No follow up

**Abbreviations:** AA: Anomic Aphasia, AmA: Amnesic Aphasia, BA: Broca's Aphasia, CA: Conduction Aphasia, FA: Fluent Aphasia, GA: Global Aphasia, MA: Mixed Aphasia, NFA: Non-Fluent Aphasia, WA: Wernicke's Aphasia.

**Table 2:** Previous studies of tDCS in Chronic Post-stroke Aphasia - Left Frontal Stimulation.

Study	Participants	Type of Stimulation	Area targeted	Number of sessions	Duration of sessions	Intensity	Speech therapy	Outcomes assessed	Results	Follow up
Fiori V, et al. [16]	3 NFA	Anodal/Sham.	Left posterior perisylvian area.	5 sessions	20 minutes	1 mA	Yes	Picture Naming test	Anodal tDCS increases accuracy.	Effects persisted for 3 weeks after treatment.
Fridriks-son J, et al. [33]	8 AA	Anodal/Sham.	Left posterior cortex.	5 sessions	20 minutes	1mA	Yes	Picture Naming test	Anodal tDCS reduces reaction time.	Effects persisted for 3 weeks after treatment.

Floel A, et al. [15]	12 1 GA, 7 BA, 2 AmA, 1 WA, 1 unclassified	Anodal/Cathodal/Sham.	Temporo-parietal junction.	3 sessions	20 minutes	1mA	Yes	Picture Naming test	Anodal tDCS increases accuracy.	Effects persisted for 2 weeks after treatment.
Fridriksson J, et al. [34]	74	Anodal/Sham.	Left temporoparietal regions	15 sessions	20 minutes	1mA	Yes	Naming test	Improvement in naming task. A-tDCS led to at least 1.5-item greater improvement in correct naming.	No follow up

**Abbreviations:** AA: Anomic Aphasia, AmA: Amnesic Aphasia, BA: Broca's Aphasia, GA: Global Aphasia, NFA: Non-Fluent Aphasia, WA: Wernicke's Aphasia.

**Table 3:** Previous studies of tDCS in Chronic Post-stroke Aphasia - Left Temporal Stimulation.

Study	Participants	Type of Stimula-tion	Area targeted	Number of sessions	Duration of sessions	Intensity	Speech therapy	Outcomes assessed	Results	Follow up
Monti A, et al. [35]	8, 4 GA, 4 BA	Anodal/Cathodal/Sham.	Right fronto-temporal cortex.	1 session	10 minutes	2mA	No	Picture Naming test	Improvement in the accuracy of the Picture Naming test 1 min after Cathodal tDCS over Broca's area.	No follow up
Kang EK, et al. [36]	10, 3 GA, 4 BA, 2 AA, 1TCA	Cathodal/Sham.	Right inferior frontal gyrus.	5 sessions.	20 minutes	2mA	Yes	Picture Naming test	Cathodal tDCS increases accuracy 1 hour following the last session.	No follow up
Vines BW, et al. [37]	6 BA	Anodal/Sham.	Right inferior frontal gyrus.	3 sessions.	20 minutes	1.2mA	Yes	Automatic speech, picture description, picture naming	Anodal tDCS improves fluency of speech.	No follow up
Jung IY, et al. [38]	37, 10 FA, 26 NFA	Cathodal.	Right inferior frontal gyrus.	10 sessions.	30 minutes	1mA	Yes	Korean version of Western Aphasia Battery	Cathodal tDCS improves the aphasia quotient.	No follow up



Marangolo P, et al. [39]	7 NFA	Anodal and Cathodal (bihemispheric stimulation)	Anodal Left Inferior Frontal Gyrus. Cathodal Right Inferior Frontal Gyrus.	10 sessions.	20 minutes	2mA	Yes	Picture description, noun naming and verb naming	Improvement in picture description, noun naming, and verb naming.	Improvement persisted at 1-week follow-up.
Cipollari S, et al. [40]	6 NFA	Anodal/Sham.	Right Inferior Frontal Gyrus.	15 sessions	20 minutes	2mA	Yes	Picture description task, oral and written noun and verb naming tasks, word repetition, reading, and writing under dictation	Improvement in speech fluency. Better accuracy for words and sentences for treated and untreated items post-treatment.	Benefits persisted at 1-week follow-up.
Shah-Basak PP, et al. [41]	12 NFA	Anodal/Cathodal/Sham	Left frontal lobe, Right frontal lobe	10 sessions	20 minutes	2mA	No	Picture Naming test	Greatest improvement in naming with Cathodal left FL stimulation.	Benefits noted at 2 weeks and 2-month follow-up.
Marangolo P, et al. [39]	9 patients. NFA	Anodal and Cathodal (bihemispheric stimulation)	Left inferior frontal gyrus (anodal) Right inferior frontal gyrus (cathodal)	15 sessions	20 minutes	2mA	Yes	Repetition of syllables produced via an auditory medium.	Improvement in speech articulation.	No follow up
Norise C, et al. [42]	9 patients. NFA	Anodal/Cathodal/Sham	Left frontal lobe, Right frontal lobe	10 sessions	20 minutes	2mA	No	Picture Naming test	Fluency improvements noted at word level and sentence level.	Better improvement noted at 2 weeks follow-up
Silva FRD, et al. [43]	14 NFA	Cathodal/Sham.	Right BA homologue.	5 sessions	20 minutes	2mA	No	Picture Naming test	No significant difference on Boston Naming Test at 1 week follow-up.	No significant difference

**Abbreviations:** AA: Anomic Aphasia, BA: Broca's Aphasia, FA: Fluent Aphasia, GA: Global Aphasia, NFA: Non-Fluent Aphasia, TCA: Transcortical Aphasia.

**Table 4:** Previous studies of tDCS in Chronic Post-stroke Aphasia - Right Hemisphere Stimulation.

STUDY	Participants	Type of Stimulation	Area targeted	Number of sessions	Duration of sessions	Intensity	Speech therapy	Outcomes assessed	Results	Follow up
Marangolo P, et al. [44]	14 NFA	Anodal/ Sham.	10th thoracic spinal vertebra.	5 sessions.	20 minutes	2mA	No	Improvement in verb naming	Improvement in verb naming	Improvement in verb naming 1 week later.
Marangolo P, et al. [45]	12 NFA	Cathodal/ Sham.	Right cerebellum	5 sessions.	20 minutes	2mA	Yes	Improvement in verb generation	Improvement in verb generation	Improvement in verb generation after treatment 1 week later.

**Abbreviations:** AA: Anomic Aphasia, BA: Broca's Aphasia, FA: Fluent Aphasia, GA: Global Aphasia, NFA: Non-Fluent Aphasia, TCA: Transcortical Aphasia.

**Table 5:** Previous studies of tDCS in Chronic Post-stroke Aphasia - Non-Cerebral Hemisphere Stimulation.

Only four studies have included patients with subacute aphasia, and the findings have been contradictory (Table 6). It has been suggested that tDCS targeting perilesional areas in the acute or subacute phase after stroke could lead to limited language improvements. In the first months after the onset, most patients can, in fact, already exhibit a partial spontaneous recovery due to specific neural mechanisms. In the acute and subacute phases, there is a dynamic interplay between the damaged and the preserved hemisphere, making it difficult to identify the areas that need to be stimulated or inhibited. Hence, application of tDCS is advisable in chronic post stroke aphasia patients rather than in acute or subacute aphasia. In the chronic stage, it becomes more feasible to determine which brain connections remain intact and which regions exhibit higher levels of activity when doing specific

cognitive activities. Furthermore, the activity around the lesion appears to be more robust and consistent six months later. For these reasons, it is often advised that tDCS be applied to perilesional areas in chronic aphasia [46]. However, there is recent evidence supporting the potentially beneficial role of rehabilitative measures in the early stages of post-stroke aphasia. Studies in speech and language therapy [47,48], transcranial magnetic current stimulation [9], and tDCS have brought forth beneficial effects in the acute-subacute phases of post-stroke aphasia. Lazar et al. observed that early intervention after stroke, such as noninvasive brain stimulation, pharmacology, or targeted behavioral methods, may enhance the natural recovery processes that occur within the first 90 days [49].

STUDY	Participants	Type of Stimulation	Area targeted	Number of sessions	Duration of sessions	Intensity	Speech therapy	Outcomes assessed	Results	Follow up
You DS, et al. [50]	21 GA	Anodal/ Cathodal/ Sham.	Anodal and Sham left superior temporal gyrus; Cathodal right superior temporal gyrus.	10 sessions.	30 minutes	2mA	Yes	Auditory verbal comprehension	Cathodal tDCS improves auditory verbal comprehension.	No follow up
Polanowska KE, et al. [51]	24 NFA	Anodal/ Sham.	Broca's area	15 sessions.	10 minutes	1mA	Yes	Boston Naming test	Anodal tDCS had higher size effect in Naming times at end of treatment.	Anodal tDCS had higher size effect in Naming times at 3 months follow up.

Spielman K, et al. [52]	58, 30 FA, 20 NFA, 8 MA	Anodal/ Sham.	Left Inferior Frontal Gyrus.	5 sessions.	20 minutes	1mA	Yes	Boston Naming test	No significant differences between anodal tDCS and sham-tDCS over the intervention period.	No significant differences between anodal tDCS and sham-tDCS on the Boston Naming Test at 6-month follow-up.
Stockbridge MD, et al. [53]	58 subacute patients.	Anodal/ Sham.	Based on fMRI results.	15 sessions.	20 minutes	1mA	Yes	Picture Naming test	No significant difference in the naming performance between baseline and 1 week post tDCS between the groups.	Statistically significant differences between groups with respect to efficiency of picture description, and change in content of picture description. No change in accuracy for untrained pictures.

**Abbreviations:** FA: Fluent Aphasia, GA: Global Aphasia, MA: Mixed Aphasia, NFA: Non-Fluent Aphasia.

**Table 6:** Previous studies of tDCS in Subacute Post-stroke Aphasia.

The studies on tDCS have indeed included patients with both fluent and non-fluent aphasia and, in several cases, anomia. Few studies have compared the effect of transcranial direct current stimulation (tDCS) in individuals with fluent and non-fluent aphasia. Generally, individuals with fluent aphasia are known to have a favourable prognosis. Young-Jung et al. found that there was no statistically significant change in the improvement of aphasia quotient percentage between fluent and non-fluent aphasic patients [38]. A post hoc analysis in a Cochrane review found that although tDCS was effective in a mixed population of aphasics, it was ineffective in a population solely comprised of non-fluent aphasics [54]. Moreover, there was no evidence of a statistically significant difference in treatment impact between subgroups based on the kind of aphasia.

Another important factor to consider is the impact of tDCS on ischemic and hemorrhagic stroke. Young-Jung et al. found that patients with hemorrhagic stroke were more likely to have favorable outcomes (odds ratio=4.897,  $p<0.05$ ) compared to those with ischemic stroke [38]. This is probably explained by the fact that patients with hemorrhagic stroke had subcortical lesions as compared to ischemic stroke. Patients with cortical lesions were more likely to experience severe

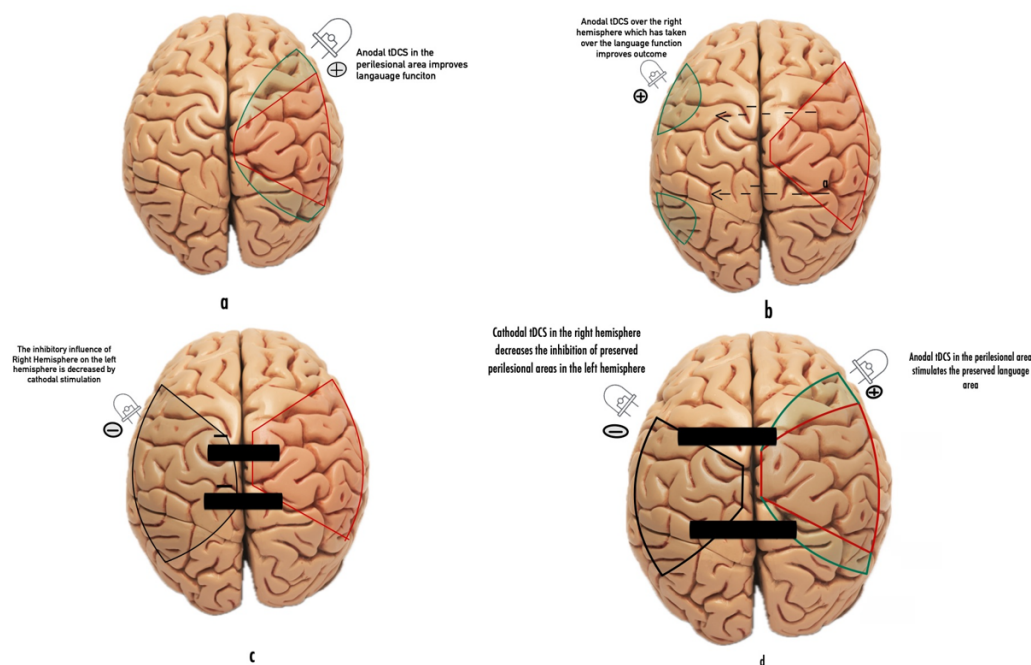
aphasia compared to those with subcortical lesions.

### Target Sites for tDCS in Post-Stroke Aphasia

The targets of stimulation in post-stroke aphasia patients have exhibited a wide range of variations. The variability observed can be partially attributed to our limited understanding of language mechanisms and circuits in healthy individuals, the mechanisms of recovery during aphasia, and the mechanisms underlying the therapeutic effects of tDCS. The putative functions of extracerebral structures in language are also accountable for the diverse sites of activation. Most studies of tDCS in post-stroke aphasia have utilized stimulation of the left cerebral hemisphere and predominantly frontal regions of the language network, focusing on Broca's area with an aim to enhance the activity of perilesional areas (Table 2). Few studies have focused on stimulation of the posterior perisylvian areas, including Wernicke's area (Table 3). In their study, You et al. observed that patients with subacute global aphasia showed greater improvement in auditory verbal comprehension after receiving cathodal tDCS compared to those who underwent anodal or sham stimulation over the left superior temporal areas [50].

Other studies have also evaluated the effect of tDCS stimulation over the right hemisphere (Table 4). The Right hemisphere can have variable effects on the recovery of language function after a stroke [55]. In certain patients, the right hemisphere can gradually take on some language functions, especially when there is decreased interhemispheric inhibition caused by the diseased left hemisphere. In this group of patients, anodal tDCS over the right hemisphere may have a beneficial effect. This pattern is more commonly observed in patients with more extensive damage to the left hemisphere, with little to no preserved perilesional tissue in that area. Melodic intonation therapy (MIT) relies on the exaggeration of the musical qualities of

speech and is another treatment technique that is predicated on the recruitment of the right hemisphere for language. Studies have shown that using right anodal tDCS along with treatments based on MIT improved verbal fluency in aphasic participants with severe left hemisphere lesions, again indicating that, especially in the subacute stages, the right hemisphere may have a facilitatory and adaptive role. In other patients, the right hemisphere may exert an increased inhibitory influence on the preserved cortical areas in the left hemisphere, and in such patients, cathodal stimulation may enhance the activity of the preserved language areas in the left hemisphere (Figure 2).



**Figure 2:** The effect of tDCS on different targets in the language area. (a) in the chronic stage, anodal stimulation of the perilesional area would lead to improvement of language function. (b) in the subacute stage, when right sided language areas may subserve the language function and anodal stimulation along with decreased inhibition from left hemisphere may help in language recovery. (c) In some patients, the right hemisphere may exert inhibition over the left hemisphere thereby preventing the activation of preserved perilesional area in the left hemisphere. Inhibition of right hemisphere by cathodal stimulation may help in recovery of the left sided preserved language areas. (d) Bihemispheric stimulation-anodal in the left hemisphere to increase activity of perilesional areas and cathodal stimulation of right hemisphere will decrease the inhibition of left hemisphere.

Conversely, a perilesional neural activation would often occur in case of a localized and less severe injury and would contribute to a better recovery [55]. Anodal stimulation of the left hemisphere or cathodal tDCS of the right hemisphere would be theoretically beneficial in such patients. Similar results have been seen with cathodal stimulation of the preserved hemisphere on motor function in stroke survivors.

In a systematic review and network metanalysis, Elsner et al. found that cathodal tDCS over the non-lesioned hemisphere led to significant improvements in activities of daily living (ADL), supporting the interhemispheric inhibition model [56]. Recently, doubts have been raised about the oversimplification or inaccuracy of the interhemispheric inhibition model. New models, such as the bimodal balance-

recovery model, have been proposed to address these concerns [57]. Therefore, conducting a functional magnetic resonance imaging (fMRI) study is advisable before performing transcranial direct current stimulation (tDCS) to identify the specific brain regions activated during particular tasks. Most fMRI studies have yielded excellent results in identifying the most active perilesional areas for a more personalized montage. Extracerebral structures such as the cerebellum and the T10 spinous process have also been analysed (Table 5).

### Outcomes Assessed for the Effect of tDCS on Post-Stroke Aphasic Patients

The effects of tDCS application can be measured in several ways. The most common method used is via behavioural measures, wherein the researchers aim to measure a given behaviour/activity that would otherwise not be observed under sham conditions. For post-stroke aphasia, the assessed outcomes included functional communication and performance in naming nouns and verbs. Very few studies have evaluated the effect of tDCS on functional communication. Elsner et al. conducted a systematic analysis and found that there were only 3 studies with 112 participants that had used functional conversation as an outcome measure [54]. They found no evidence of the effect of tDCS on functional conversation. In the same meta-analysis, authors found an effect of anodal tDCS on naming nouns (11 studies with 298 patients; SMD = 0.51; 95% CI 0.11 to 0.90), but there was no effect of cathodal or dual tDCS. There was no evidence of any effect of tDCS on naming verbs. According to a Cochrane review, there was a statistically significant effect of active tDCS (including combined treatment groups, anodal, cathodal, and dual) at the end of the intervention period for improving performance in naming nouns (SMD 0.42, 95% CI 0.19 to 0.66). However, there was no significant effect for naming verbs (SMD 0.19, 95% CI -0.68 to 1.06) [58]. Considering the likelihood of a limited connection between language function (such as naming ability of nouns) following a stroke and functional communication scores, enhancing language function may not necessarily lead to a corresponding enhancement in performance during everyday communication scenarios.

### Combining other Rehabilitation Strategies with tDCS

It is often recommended to integrate tDCS with other rehabilitation therapies to optimize the success of a language recovery program. Several studies have focused on coupling stimulation techniques with SLT, mostly to improve anomia. The speech therapy methods used were stimulation with auditory and visual sense, such as Melodic Intonation Therapy, Visual Action Therapy, and Auditory

Comprehension Training. Intensive SLT alone can relieve symptoms in chronic post-stroke aphasia, but effect sizes are moderate and combination with anodal tDCS can have significant benefits in naming and communication abilities. tDCS for post-stroke aphasia can be performed either as an offline method or an online method. Some studies have reported enhanced performance when tDCS is applied concurrently with a language task such as naming pictures of objects or video clips. It is one way to potentiate the impact of tDCS, as the neurons involved in the task are thought to be more sensitive to the polarising effects of tDCS. The concurrent usage of tDCS and the task is termed “online.” In contrast, in the “offline” method, the requisite testing is performed before the tDCS sessions, and the benefits, if any, are noted by performing the tests again after the completion of the session.

### Conclusion

To conclude, despite the heterogeneity of the studies regarding parameters, site, duration, frequency, and outcomes of stimulation, transcranial direct current stimulation (tDCS) has been shown to enhance language performance in healthy individuals and patients with aphasia. While tDCS is generally considered safe, certain high-risk individuals have been excluded from most of the studies - individuals with a history of epilepsy, psychiatric or neurological conditions such as brain tumors, and individuals using certain medications. As our understanding of language circuits, mechanisms of aphasia recovery, and mechanisms underlying the beneficial effects of tDCS continue to improve, it brings forth the idea that mere cathodal or anodal stimulation over an area would not necessarily bring about desired beneficial changes. Beneficial effects probably depend upon the stroke's size, type of stroke (ischemic vs hemorrhagic), the site of the stroke, recovery processes that have taken place, and exactly which areas of the two hemispheres are functioning and subserving the language function. Additionally, in almost all studies using tDCS for aphasia, tDCS has not been used in isolation but has always been used in conjunction with other rehabilitative measures, as would be done in real life. However, the American Heart Association recommends that “inclusion of behavioral training in the majority of tDCS/aphasia studies may inhibit an understanding of what tDCS does autonomously to language functions” [5]. Though one can argue that an aphasia experiment without language training would deprive aphasic subjects of concomitant proven therapy, it might also enable a better understanding of tDCS, introducing better paradigms that can then be combined with previously proven methods of rehabilitation. The majority of studies have concentrated on chronic aphasia, which hampers the ability to draw broad conclusions from the data. The impact of transcranial direct current stimulation (tDCS) on acute and subacute aphasia



is still unclear and requires further investigation. Finally, and most importantly, the studies' endpoints have generally been naming on Picture Naming Tests or similar tests. It is unclear if improvements in noun and verb naming result in meaningful changes in functional communication and quality of life. As further information emerges, efforts would also need to be made for more meaningful improvements and recoveries.

## References

1. Feigin VL, Stark BA, Johnson CO, Roth GA, Bisignano C, et al. (2021) Global, Regional, and National Burden of Stroke and Its Risk Factors, 1990–2019: A Systematic Analysis for the Global Burden of Disease Study 2019. *The Lancet Neurology* 20(10): 795-820.
2. Gronberg A, Henriksson I, Stenman M, Lindgren AG (2022) Incidence of aphasia in Ischemic Stroke. *Neuroepidemiology* 56(3): 174-182.
3. Mitchell C, Gittins M, Tyson S, Vail A, Conroy P, et al. (2021) Prevalence of Aphasia and Dysarthria among Inpatient Stroke Survivors: Describing the Population, Therapy Provision and Outcomes on Discharge. *Aphasiology* 35(7): 950-960.
4. Pauranik A, George A, Sahu A, Nehra A, Paplikar A, et al. (2019) Expert Group Meeting on Aphasia: A Report. *Annals of Indian Academy of Neurology* 22(2): 137-146.
5. Wortman-Jutt S, Edwards DJ (2017) Transcranial Direct Current Stimulation in Poststroke Aphasia Recovery. *Stroke* 48(3): 820-826.
6. Fridriksson J, Hillis AE (2021) Current approaches to the treatment of post-stroke aphasia. *Journal of stroke* 23(2): 183-201.
7. Nouwens F, Visch-Brink EG, Sandt-Koenderman MM, Dippel DW, Koudstaal PJ, et al. (2015) Optimal Timing of Speech and Language Therapy for Aphasia After Stroke: More Evidence Needed. *Expert Rev Neurother* 15(8): 885-893.
8. Berthier ML (2005) Poststroke Aphasia: Epidemiology, Pathophysiology and Treatment. *Drugs Aging* 22(2): 163-182.
9. Arheix-Parras S, Barrios C, Python G, Cogne M, Sibon I, et al. (2021) A Systematic Review of Repetitive Transcranial Magnetic Stimulation in Aphasia Rehabilitation: Leads for Future Studies. *Neurosci Biobehav Rev* 127: 212-241.
10. Zettin M, Bondesan C, Nada G, Varini M, Dimitri D (2021) Transcranial Direct-Current Stimulation and Behavioral Training, a Promising Tool for a Tailor-Made Post-stroke Aphasia Rehabilitation: A Review. *Front Hum Neurosci* 15: 742136.
11. Iyer MB, Mattu U, Grafman J, Lomarev M, Sato S, et al. (2005) Safety and Cognitive Effect of Frontal DC Brain Polarization in Healthy Individuals. *Neurology* 64(5): 872-875.
12. Fertonani A, Rosini S, Cotelli M, Rossini PM, Miniussi C (2010) Naming Facilitation Induced by Transcranial Direct Current Stimulation. *Behavioral Brain Research* 208(2): 311-318.
13. DeVries MH, Barth AC, Maiworm S, Knecht S, Zwieterlood P, et al. (2010) Electrical Stimulation of Broca's Area Enhances Implicit Learning of an Artificial Grammar. *Journal of Cognitive Neuroscience* 22(11): 2427-2436.
14. Liuzzi G, Freundlieb N, Ridder V, Hoppe J, Heise K, et al. (2010) The Involvement of the Left Motor Cortex in Learning of a Novel Action Word Lexicon. *Current Biology* 20(19): 1745-1751.
15. Floel A, Rosser N, Michka O, Knecht S, Breitenstein C (2008) Noninvasive Brain Stimulation Improves Language Learning. *Journal of Cognitive Neuroscience* 20(8): 1415-1422.
16. Fiori V, Coccia M, Marinelli CV, Vecchi V, Bonifazi S, et al. (2011) Transcranial Direct Current Stimulation Improves Word Retrieval in Healthy and Nonfluent Aphasic Subjects. *Journal of cognitive neuroscience* 23(9): 2309-2323.
17. Nitsche MA, Fricke K, Henschke U, Schlitterlau A, Liebetanz D, et al. (2003) Pharmacological Modulation of Cortical Excitability Shifts Induced by Transcranial Direct Current Stimulation in Humans. *J Physiol* 553(Pt 1): 293-301.
18. Suzuki K, Fujiwara T, Tanaka N, Tsuji T, Masakado Y, et al. (2012) Comparison of the After-Effects of Transcranial Direct Current Stimulation over the Motor Cortex in Patients With Stroke and Healthy Volunteers. *International Journal of Neuroscience* 122(11): 675-681.
19. Hesse S, Werner C, Schonhardt EM, Bardeleben A, Jenrich W, et al. (2007) Combined Transcranial Direct Current Stimulation and Robot-Assisted Arm Training in Subacute Stroke Patients: A Pilot Study. *Restorative Neurology and Neuroscience* 25(1): 9-15.
20. Baker JM, Rorden C, Fridriksson J (2010) Using Transcranial Direct-Current Stimulation to Treat Stroke Patients with Aphasia. *Stroke* 41(6): 1229-1236.



21. Marangolo P, Marinelli CV, Bonifazi S, Fiori V, Ceravolo MG, et al. (2011) Electrical Stimulation Over the Left Inferior Frontal Gyrus (IFG) Determines Long-Term Effects in the Recovery of Speech Apraxia in Three Chronic Aphasics. *Behav Brain Res* 225(2): 498-504.
22. Marangolo P, Fiori V, Calpagnano MA, Campana S, Razzano C, et al. (2013) tDCS Over the Left Inferior Frontal Cortex Improves Speech Production in Aphasia. *Front Hum Neurosci* 7: 539.
23. Volpato C, Cavinato M, Piccione F, Garzon M, Meneghello F, et al. (2013) Transcranial Direct Current Stimulation (TDCS) of Broca's Area In Chronic Aphasia: A Controlled Outcome Study. *Behav Brain Res* 247: 211-216.
24. Polanowska KE, Lesniak M, Seniow JB, Członkowska A (2013) No Effects of Anodal Transcranial Direct Stimulation on Language Abilities in Early Rehabilitation of Post-Stroke Aphasic Patients. *Neurol Neurochir Pol* 47(5): 414-422.
25. Vestito L, Rosellini S, Mantero M, Bandini F (2014) Long-Term Effects of Transcranial Direct-Current Stimulation in Chronic Post-Stroke Aphasia: A Pilot Study. *Front Hum Neurosci* 8: 785.
26. Campana S, Caltagirone C, Marangolo P (2015) Combining Voxel-Based Lesion-Symptom Mapping (VLSM) with A-TDCS Language Treatment: Predicting Outcome of Recovery in Nonfluent Chronic Aphasia. *Brain Stimulation* 8(4): 769-776.
27. Wu D, Wang J, Yuan Y (2015) Effects of Transcranial Direct Current Stimulation on Naming and Cortical Excitability in Stroke Patients with Aphasia. *Neurosci Lett* 589: 115-120.
28. Meinzer M, Darkow R, Lindenberg R, Floel A (2016) Electrical Stimulation of the Motor Cortex Enhances Treatment Outcome in Post-Stroke Aphasia. *Brain* 139(Pt 4): 1152-1163.
29. Branscheidt M, Hoppe J, Zwitterlood P, Liuzzi G (2018) tDCS Over the Motor Cortex Improves Lexical Retrieval of Action Words in Poststroke Aphasia. *J Neurophysiol* 119(2): 621-630.
30. Santos MDD, Cavenaghi VB, Mac-Kay APMG, Serafim V, Venturi A, et al. (2017) Non-Invasive Brain Stimulation and Computational Models in Post-Stroke Aphasic Patients: Single Session of Transcranial Magnetic Stimulation and Transcranial Direct Current Stimulation. A Randomized Clinical Trial. *Sao Paulo Med J* 135(5): 475-480.
31. Woodhead ZVJ, Kerry SJ, Aguilar OM, Ong YH, Hogan JS, et al. (2018) Randomized Trial of Ireadmore Word Reading Training and Brain Stimulation in Central Alexia. *Brain* 141(7): 2127-2141.
32. Pestalozzi MI, Di Pietro M, Martins Gaytanidis C, Spierer L, Schnider A, et al. (2018) Effects of Prefrontal Transcranial Direct Current Stimulation on Lexical Access in Chronic Poststroke Aphasia. *Neurorehabil Neural Repair* 32(10): 913-923.
33. Fridriksson J, Richardson JD, Baker JM, Rorden C (2011) Transcranial Direct Current Stimulation Improves Naming Reaction Time in Fluent Aphasia: A Double-Blind, Sham-Controlled Study. *Stroke* 42(3): 819-821.
34. Fridriksson J, Rorden C, Elm J, Sen S, George MS, et al. (2018) Transcranial Direct Current Stimulation vs Sham Stimulation to Treat Aphasia After Stroke: A Randomized Clinical Trial. *JAMA Neurol* 75(12): 1470-1476.
35. Monti A, Cogiamanian F, Marceglia S, Ferrucci R, Mameli F, et al. (2008) Improved Naming After Transcranial Direct Current Stimulation in Aphasia. *J Neurol Neurosurg Psychiatry* 79(4): 451-453.
36. Kang EK, Kim YK, Sohn HM, Cohen LG, Paik NJ (2011) Improved Picture Naming in Aphasia Patients Treated with Cathodal tDCS to Inhibit the Right Broca's Homologue Area. *Restor Neurol Neurosci* 29(3): 141-152.
37. Vines BW, Norton AC, Schlaug G (2011) Non-Invasive Brain Stimulation Enhances the Effects of Melodic Intonation Therapy. *Front Psychol* 2: 230.
38. Jung IY, Lim JY, Kang EK, Sohn HM, Paik NJ (2011) The Factors Associated with Good Responses to Speech Therapy Combined with Transcranial Direct Current Stimulation in Post-stroke Aphasic Patients. *Ann Rehabil Med* 35(4): 460-469.
39. Marangolo P, Fiori V, Gelfo F, Shofany J, Razzano C, et al. (2014) Bihemispheric tDCS Enhances Language Recovery but Does Not Alter BDNF Levels in Chronic Aphasic Patients. *Restorative Neurology and Neuroscience* 32(2): 367-379.
40. Cipollari S, Veniero D, Razzano C, Caltagirone C, Koch G, et al. (2015) Combining TMS-EEG with Transcranial Direct Current Stimulation Language Treatment in Aphasia. *Expert Rev Neurother* 15(7): 833-845.
41. Shah-Basak PP, Norise C, Garcia G, Torres J, Faseyitan O, et al. (2015) Individualized Treatment with Transcranial Direct Current Stimulation in Patients with Chronic Non-

- Fluent Aphasia Due to Stroke. *Front Hum Neurosci* 9: 201.
42. Norise C, Sacchetti D, Hamilton R (2017) Transcranial Direct Current Stimulation in Post-stroke Chronic Aphasia: The Impact of Baseline Severity and Task Specificity in a Pilot Sample. *Front Hum Neurosci* 11: 260.
  43. Silva FRD, Mac-Kay APMG, Chao JC, Santos MDD, Gagliardi RJ (2018) Transcranial Direct Current Stimulation: A Study on Naming Performance in Aphasic Individuals. *Codas* 30(5): e20170242.
  44. Marangolo P, Fiori V, Shofany J, Gili T, Caltagirone C, et al. (2017) Moving Beyond the Brain: Transcutaneous Spinal Direct Current Stimulation in Post-Stroke Aphasia. *Front Neurol* 8: 400.
  45. Marangolo P, Fiori V, Caltagirone C, Pisano F, Priori A (2018) Transcranial Cerebellar Direct Current Stimulation Enhances Verb Generation But Not Verb Naming in Poststroke Aphasia. *Journal of Cognitive Neuroscience* 30(2): 188-199.
  46. Stefaniak JD, Halai AD, Lambon Ralph MA (2020) The Neural and Neurocomputational Bases of Recovery from Post-Stroke Aphasia. *Nature Reviews Neurology* 16(1): 43-55.
  47. Godecke E, Hird K, Lalor EE, Rai T, Phillips MR (2012) Very Early Poststroke Aphasia Therapy: A Pilot Randomized Controlled Efficacy Trial. *Int J Stroke* 7(8): 635-644.
  48. Godecke E, Ciccone NA, Granger AS, Rai T, West D, et al. (2014) A Comparison of Aphasia Therapy Outcomes Before and After a Very Early Rehabilitation Programme Following Stroke. *Int J Lang Commun Disord* 49(2): 149-161.
  49. Gerstenecker A, Lazar RM (2019) Language Recovery Following Stroke. *The Clinical Neuropsychologist* 33(5): 928-947.
  50. You DS, Kim DY, Chun MH, Jung SE, Park SJ (2011) Cathodal Transcranial Direct Current Stimulation of the Right Wernicke's area Improves Comprehension in Subacute Stroke Patients. *Brain Lang* 119(1): 1-5.
  51. Polanowska KE, Lesniak MM, Seniow JB, Czepiel W, Czlonkowska A (2013) Anodal Transcranial Direct Current Stimulation in Early Rehabilitation of Patients with Post-Stroke Non-Fluent Aphasia: A Randomized, Double-Blind, Sham-Controlled Pilot Study. *Restor Neurol Neurosci* 31(6): 761-771.
  52. Spielmann K, Sandt-Koenderman WME, Heijenbrok-Kal MH, Ribbers GM (2018) Transcranial Direct Current Stimulation Does Not Improve Language Outcome in Subacute Poststroke Aphasia. *Stroke* 49(4): 1018-1020.
  53. Stockbridge MD, Elm J, Breining BL, Tippet DC, Sebastian R, et al. (2023) Transcranial Direct-Current Stimulation in Subacute Aphasia: A Randomized Controlled Trial. *Stroke* 54(4): 912-920.
  54. Elsner B, Kugler J, Pohl M, Mehrholz J (2019) Transcranial Direct Current Stimulation (tDCS) for Improving Aphasia in Adults with Aphasia After Stroke. *Cochrane Database of Systematic Reviews* 5(5): CD009760.
  55. Hamilton RH, Chrysikou EG, Coslett B (2011) Mechanisms of Aphasia Recovery after Stroke and the Role of Noninvasive Brain Stimulation. *Brain Lang* 118(1-2): 40-50.
  56. Elsner B, Kwakkel G, Kugler J, Mehrholz J (2017) Transcranial Direct Current Stimulation (tDCS) For Improving Capacity in Activities and Arm Function after Stroke: A Network Meta-Analysis of Randomized Controlled Trials. *Journal of Neuroengineering and Rehabilitation* 14(1): 95.
  57. Pino G, Pellegrino G, Assenza G, Capone F, Ferreri F, et al. (2014) Modulation of Brain Plasticity in Stroke: A Novel Model for Neurorehabilitation. *Nature Reviews Neurology* 10(10): 597-608.
  58. Marangolo P, Fiori V, Sabatini U, Pasquale G, Razzano C, et al. (2016) Bilateral Transcranial Direct Current Stimulation Language Treatment Enhances Functional Connectivity in the Left Hemisphere: Preliminary Data from Aphasia. *J Cogn Neurosci* 28(5): 724-738.