



Management of Deep Carious Lesions: A Systematic Review and Meta-Analysis

Hanan A.N. Soliman^{1*}, Hamdi H. Hamama², Radwa Eltoukhy^{2,3} and Salah H. Mahmoud⁴

¹Assistant professor, Conservative Dentistry Department, Faculty of Dentistry, Kafrelsheikh University, Egypt

²Associate professor, Conservative Dentistry Department, Faculty of Dentistry, Mansoura university, Egypt

³Associate professor, Conservative Dentistry Department, Faculty of Dentistry, Horus University, New-Damietta, Egypt

⁴Professor, Conservative Dentistry Department, Faculty of Dentistry, Mansoura University, Egypt

***Corresponding author:** Hanan Ahmed Nabil Soliman, Assistant professor, Conservative Dentistry Department, Faculty of Dentistry, Kafrelsheikh University 33516, Egypt, Email: hananahmed@den.kfs.edu.eg

Received Date: March 21, 2024; **Published Date:** April 15, 2024

Abstract

Objectives: Our objective was to evaluate the effectiveness of techniques and pulp-capping materials used to maintain pulp vitality in extensively carious lesions.

Materials and Methods: We conducted an electronic search to collate studies published from 2009 to 2019 that showed clinical and radiological success of pulp-capping materials after removal of deep carious lesions. We performed meta-analysis to compare two calcium silicate-based cements (CSC) for pulp protection and hard tissue barrier formation after vital pulp therapy.

Results: Sixteen clinical trials were included in the systematic review. The mean follow-up duration was 26.88 months. The majority of the clinical trials included in this review used complete caries removal technique (CCRT), whereas four studies utilized incomplete caries removal technique (ICRT). ICRT reported lower risk of pulp exposure than CCRT. One-step ICRT with absence of pulpal inflammation enhanced the results. Direct pulp-capped teeth with opened apex, minute exposure with no pulpal inflammation, and well-sealed restoration showed higher success in pulp healing. The risk of bias widely differed between studies. Meta-analysis reported no significant difference between both materials in different pulp therapies.

Conclusions: ICRT had a significantly higher success rate than CCRT. The clinical observation, extent and depth of caries, location and size of pulp exposure, pulpal bleeding, and patient age were predictive factors used to assess the success rate of deep caries removal techniques. There is no significant difference in clinical performance between different CSC.

Clinical Relevance: Incomplete CRT seems suitable to treat deep carious lesions. No specific CSC can be recommended.

Keywords: Back Pain; Musculoskeletal Diseases; Prevalence

Introduction

Untreated carious lesions in human teeth are a dominant disease worldwide. Deep carious lesions and considerably extensive restorative strategies with or without pulp exposure have an invariable outcome on pulp inflammation,

as either reversible or irreversible pulpitis [1].

One of the most controversial dilemmas in dentistry is management of deep carious lesions. There are two schools of thought regarding the management of such cases: either a conservative approach with vital pulp therapy (VPT) or

an invasive root canal treatment. vital pulp therapy aims to maintain and conserve dental pulp tissue that is in jeopardy but has not been destroyed by trauma, caries, or restorative procedures [2].

Vital pulp therapy is practiced in one of four conservative treatment modalities depending (e.g., indirect pulp capping, direct pulp capping, partial pulpotomy and full pulpotomy) on the remaining dentin layer and size of the pulp exposure. When pulp is nearly exposed, a protective biomaterial dressing called a “pulp capping agent” is placed over the remaining thin dentin layer. When there is exposed coronal pulp, a direct pulp capping technique is performed on the exposed pulp while a pulpotomy is performed to either partially remove coronal pulp tissue or complete amputation of the coronal pulp [3]. In addition, there are clinical strategies to protect pulp vitality in teeth with deep caries, either a 1-step partial caries removal or a 2-step stepwise excavation [4]. Thus, the total removal of all carious lesions is no longer considered obligatory.

An ideal pulp capping material should fulfill the following requirements. It should adhere to tooth substrates, keep up a hermetic seal that is insoluble in tissue fluids, be non-resorbable, have dimensional stability, be radiopaque, and display bioactivity and biocompatibility with no toxicity, carcinogenicity, or genotoxicity. Unfortunately, none of the pulp capping materials currently available satisfy all of these requirements [5].

Calcium hydroxide (CH) is one of the most common agents broadly applied in direct pulp therapy. CH promotes the formation of tertiary dentin, but it produces a necrotic layer because of its high alkalinity (pH = 12), which may lead to inflammatory pulp responses [4]. CH also has physical limitations, such as poor bonding to dentin, tunnel defects, dissolution in internal fluids, and failure of resistance under tooth flexure. For these reasons, there is ongoing research to find new materials for direct pulp therapy [6].

Nowadays, bioactive materials, such as mineral tricalcium silicate (MTA), calcium silicate cements (CSCs) (including Biodentine and Theracal LC), and calcium-enriched matrix (CEM), have attracted attention as efficient replacements for CH because of their clinical bioactivity [7].

The primary objective of our study was to provide, based on scientific evidence, a decision making process for clinicians to recommend methods to preserve pulp vitality without pulp exposure (e.g., stepwise technique, partial excavation) as opposed to complete caries removal in extensively carious teeth. The secondary objective was to evaluate the efficacy of pulp capping materials and effective techniques for preservation of pulp vitality.

These objectives were based on two research questions: (1) How effective are the different methods and pulp capping materials for preserving pulp vitality in the management of deep carious lesions? (2) What are the predictive factors that may influence clinical outcomes of the different deep caries removal techniques and VPT?

Materials & Methods

Selection Criteria

Clinical trials from 2009 or later were utilized. People who participated in these trials had permanent teeth with deep dentin caries requiring a restoration. The effect measure was realized by determining that healing of either pulp or periapical tissue had occurred. For different caries removal techniques and VPT, these criteria were applied using two parameters. (1) The clinical parameters of successful vital pulp therapy are lack of complains from the patients, positive response to a sensibility test (thermal and electrical) and no sensitivity to percussion in order to maintain pulp vitality. (2) The radiographic parameters measuring the preservation of normal periapical tissues, continued root development in immature teeth, and the absence of periapical pathosis besides formation of a calcific hard-tissue bridge.

Search Strategies

An electronic search was done by one of the authors (H.S.) for articles regarding clinical trials published in English from 2009 to July 2019 via several databases: Scopus, PubMed (MedLine), Web of Science, Ebisco Lilacs, Ibecs, SciELO, and The Cochrane Library. The search strategy used was initially developed for PubMed (MedLine) and adjusted for use in other databases. The references cited in the included studies were also checked to identify other potentially relevant studies, in addition to the hand search. After the articles were identified in the databases, they were imported into Endnote X7 software (Thompson Reuters, Philadelphia, PA, USA) to eliminate duplicates. Two reviewers independently evaluated and selected studies that met the inclusion criteria. A third reviewer was consulted when there was uncertainty regarding eligibility, and a decision was arrived at by consensus.

Study Selection

Two reviewers independently assessed the titles and abstracts of all studies. The inclusion criteria were randomized or non-randomized clinical trials including treatment of vital permanent teeth with deep cariously exposed, unexposed, or nearly exposed pulp. All subjects had to have deep carious lesions treated with or without pulp capping materials. Evaluation of success was based on both clinical and radiographic examination.

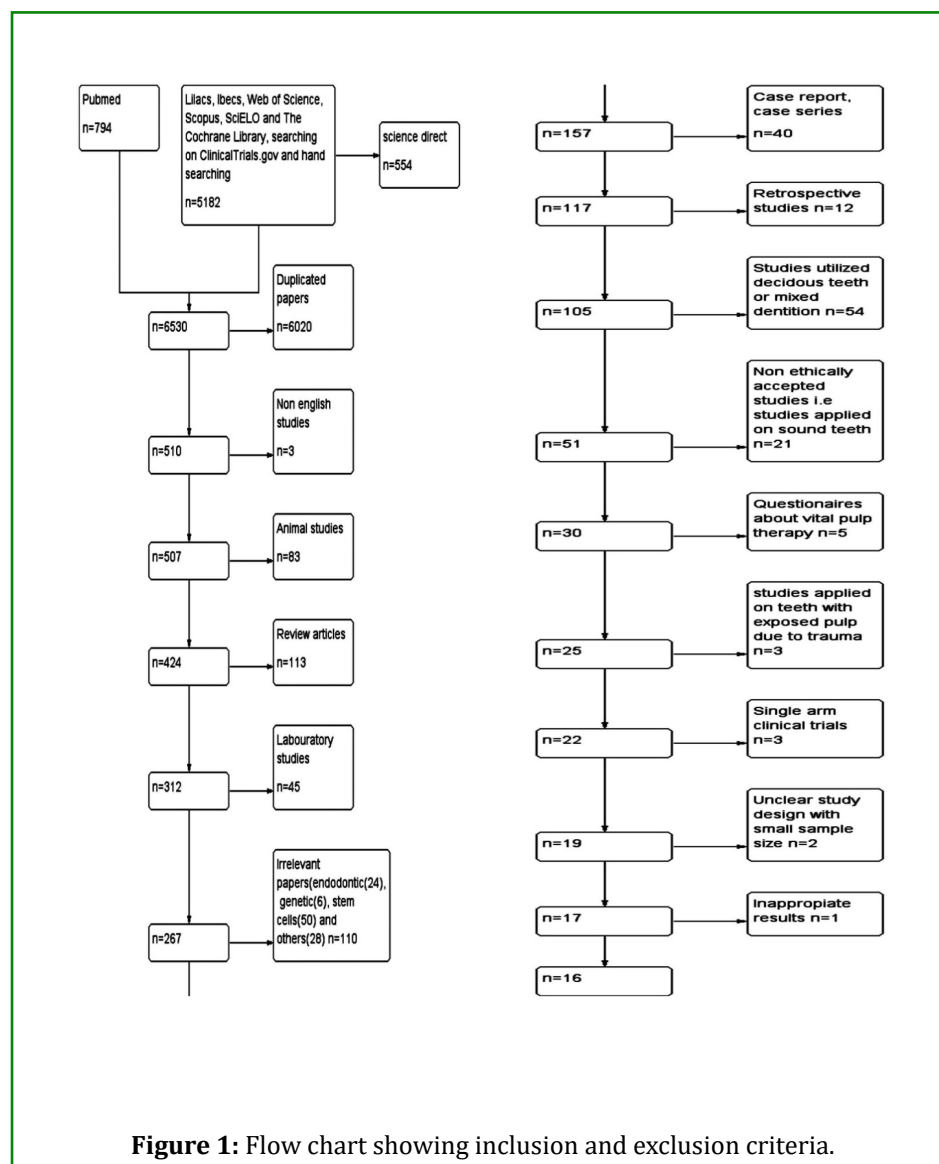
The exclusion criteria during the selection process were studies published before 2009, non-English clinical trials, animal studies, narrative and systematic reviews, case reports, laboratory studies, and retrospective clinical trials. Furthermore, the entire CT, which was performed on sound teeth that depended on postoperative extraction for histopathological examination, was excluded for ethical reasons. The patients were not medically compromised (Figure 1).

Results

The initial search through the Science Direct database resulted in 6300 articles. This was followed by a subsequent search of three other databases, which added further articles. Thus, the total number of original articles was 6530. After subtraction of duplicate articles, there were

510 remaining articles. From these, three articles were not in English, 83 were animal based, 113 were review articles, 45 were laboratory studies, 40 were case reports and case series, 12 were retrospective studies, 110 were irrelevant studies, 54 involved deciduous teeth or mixed dentition, 21 were nonethically accepted studies, 5 were questionnaires, three studies were about exposed pulp due to trauma, three were single arm clinical trials, two clinical trials compared VPT with root canal treatment, two had unclear designs with small sample size, and one unreported results.

Finally, 16 clinical trials fit the inclusion criteria of this systematic review. The detailed study selection procedure is presented in a flow chart in Figure 1. The selected clinical trials had the following geographic distribution: 6 were from Asia (37.5%), 5 from Europe (31.25%), 4 from South America (25 %), and one from Australia (6.25 %) (Figure 2).



Study	Objective	Methodology	Result	Conclusion	Risk of bias Comments (GRADE guidelines)
Bjørndal, et al. [1]	-Report the 5 year outcome of stepwise excavation versus complete excavation of deep carious lesion of permanent teeth in adult patients.	Patients with more than 18 years had a carious permanent teeth that were radiographically involved about 75% or more of the dentin thickness. In a consequent study, 58 patients who had pulp exposure were then randomized in to direct capping or partial pulpotomy.	In this long-term study, the “stepwise removal” group had a considerably higher proportion of achievement (60.2%) in comparison with the complete carious removal till reaching hard dentin group (46.3%) ($P = 0.031$). Pulp exposure rate was significantly higher in the complete caries removal than “stepwise carious removal group” (35.5% vs. 21.2%; $P = 0.014$). Patients with exposed pulps showed no statistical difference between the direct pulp capping and partial pulpotomy groups (31.8 %vs 34.5% $p= 0.92$) Presence of pre- treatment pain was obviously associated with treatment failure.	The incomplete caries removal group had a more significant level of pulps with sustained vitality without apical radiolucency compared to complete carious removal of deep carious lesions in permanent teeth at 5-year follow-up. The study could not detect any difference in the result between the direct pulp capping and partial pulpotomy groups in patients with exposed pulps.	Low risk of bias
Pereira, et al. [2]	To compare the outcome of “stepwise caries removal” with and without the use of a calcium hydroxide liner in conjunction with resin-modified glass ionomer restorations.	The authors included 98 patients between the ages of 15 and 30 who suffered from deep carious lesions in posterior teeth. The authors measured the thickness of the dentine radiographically and documented its color, consistency and moisture, as well as the bacterial count of the lesions. After “partial caries removal”, participants were randomly allocated to provisionally restore caries using RMGI with (control group) or without (test group) a calcium hydroxide liner. The main outcome was tooth vitality after 90 days. Secondary outcomes involved changes in dentinal, radiographic, and microbiological properties of the lesions.	The authors did not discover any statistically significant differences between test and control groups in tooth vitality after 3- months follow-up. Despite the utilization of the calcium hydroxide liner, the authors noticed darker, drier, harder, less contaminated dentin after temporary restorations, but the remaining dentin thickness did not change.	Using a calcium hydroxide liner during “stepwise caries excavation” and provisional restoration did not offer any extra advantage based on this 3-month clinical trial outcome.	High risk of bias Short Follow-up time (3 months) One investigator only.

Durmus, et al. [3]	To assess the clinical and microbiological efficiency of the ozone application in “stepwise excavation”.	<p>A number of 105 lower first molar teeth with deep caries lesion were involved and randomly allocated into three groups. The study included stepwise excavation treatment with no disinfectant (control), with 60 s 2% chlorhexidine digluconate (CHX) or 60 s ozone application. Moreover, recording of dentin humidity, consistency, and color features in four different stages (after initial excavation, ozone/CHX application before the provisional restoration, immediately after final excavation, 4 months later) to assess the clinical features properties of the tissue, and regular dentin samples were collected for the microbiological examination of lactobacilli, mutans streptococci, and the entire number of colony-forming units.</p>	<p>On the basis of 4 months, the remaining dentin became drier, harder, and darker in all groups. Nonetheless, CHX and ozone application were statistically better than the control group. There was a gradual lessening in the all-out number of microorganisms in all groups. Though cavity disinfectant applications were enhanced, the antibacterial efficiency (control, 79.11%; CHX, 98.39%; ozone, 93.33%), CHX application showed greater reduction than both groups ($p = 0.000$).</p>	The two-visit stepwise excavation submitted satisfactory results in decreasing the number of microorganisms and arresting caries. Additionally, disinfectant application particularly chlorhexidine might potentiate these effects and support the treatment success.	High risk of bias Short Follow-up time (4 months)
Parinyaprom, et al. [4]	To check the success rate of direct pulp capping by using either Biodentine or “Mineral Trioxide Aggregate” in the cariously exposed permanent teeth of 6- to 18 years old patients.	<p>A number of 59 cariously exposed permanent teeth diagnosed with normal pulp, reversible pulpitis or irreversible pulpitis, early periapical involvement and exposure sizes up to 2.5 mm. Each patient with only 1 tooth carefully exposed was randomly allocated to DPC with ProRoot MTA ($n = 30$) or Biodentine ($n = 29$). Patients were called up every 6 months for clinical and radiographic evaluations to determine success.</p>	<p>Fifty-five patients (mean age, 10 ± 2 years), treated with either Biodentine or “ProRoot MTA”, were involved in the examination. At mean follow-up of 18.9 ± 12.9 months, the success rate was 96.4% with Biodentine and 92.6% with ProRoot MTA.</p>	Biodentine was equivalent to “ProRoot MTA” when used as a DPC material for cariously exposed permanent teeth of 6- to 18-year-old patients. Biodentine did not cause any discoloration in this study.	Low risk of bias

Uesrichai, et al. [5]	To detect the efficiency of partial pulpotomy by using either Biodentine or ProRoot MTA in permanent teeth of 6- to 18-years old patients with subjective and objective findings showing irreversible pulpitis.	A number of 69 permanent first molars with subjective and objective findings indicating of irreversible pulpitis were involved. All operators performed PP under a standardized protocol with either Pro-Root MTA (37 teeth) or Biodentine (32 teeth) and were finally restored with composite resin or stainless steel crowns. Patients were recalled every 6 months for clinical and radiographic evaluation.	There were not any variances in the base variables (gender, age, tooth type, stage of root development, periapical state, final restoration and follow-up period) between the groups. Overall success in both groups was 90%, with 92% for ProRoot MTA and 87% for Biodentine (difference, 5%; 95% confidence interval, 9% to 19%, P = 0.487)	Permanent teeth with subjective and objective findings indicating of irreversible pulpitis in 6-18 year-old patients were successfully treated with partial pulpotomy using both cements. Biodentine displayed less frequency of discoloration than did ProRoot MTA.	Low risk of bias
Lama Awawdeh, et al. [6]	To differentiate between the clinical performance of white MTA and Biodentine in mature permanent teeth with cariously pulp exposure.	A number of 68 vital permanent teeth with deep caries in patients were randomly allocated into two material groups: MTA and Biodentine. Teeth were assessed clinically and radiographically before the procedure then standardized protocol was performed. Follow-ups were performed by a blinded calibrated evaluator after half, 1, 2, and 3 years.	There were no significant differences in the overall success rate between Biodentine and MTA; it was 93.3% at 6 months. The overall success rate increased to 96.2% at 1 year and to 100% at 2 years. At the 3-year follow-up, it decreased to 93.8%.	MTA and Biodentine have favorable and equivalent success rates if used in direct capping of the pulp or in the pulpotomy of permanent teeth with carious exposure. The duration of the coronal restoration and the remaining tooth structure may affect the durability of "Vital pulp therapy".	Moderate risk of bias One investigator only. Interexaminer and intraexaminer calibration test >1 tooth per patient
Katge, et al. [7]	To compare MTA and Biodentin in direct pulp capping clinically and radiographically in young permanent molars of 7- to 9 years old children.	According to the split mouth design, patients were then divided into 2 groups, the MTA group (left side) and the Biodentine group (right side). The pulp capping procedure was performed in 58 asymptomatic bilateral permanent molars, having pulp exposure. At each recall (baseline, 6 and 12 months), the outcome of the treatment was assessed clinically by pulp sensitivity tests and radiographically to evaluate the formation of the dentin bridge.	The study reported 100% success rate with both MTA and Biodentin at baseline, 6- and 12-month follow-up on the basis of clinical and radiographic parameters. These findings were no significant difference (P < .05) between both groups. Dentin bridge formation, through radiographic evaluation, was not evident with both groups at baseline, but it was evident after 6- and 12-month follow-up.	This study registered 100% success rate with both MTA and Biodentin when used as direct pulp-capping agents in permanent molars of 7- to 9-year-old children.	High risk of bias _Number and blindness of investigators were not reported. _Unreported interexaminer and intraexaminer calibration test _Short Follow up time (one year) Involvement of bilateral molars. smaller sample size

Brizuela, et al. [8]	To confirm the efficacy of calcium silicate materials as replacement materials for CH in direct pulp capping techniques.	A randomized clinical trial was conducted that included 169 patients (mean age, 11.3 years). The inclusion criterion was patients with 1 carious permanent tooth with pulpal exposure, a candidate for a direct pulp capping procedure. The patients were randomly allocated to one of the experimental groups (CH, Biodentine, or mineral trioxide aggregate). Clinical follow-up examinations were performed at 1 week, 3 months, 6 months, and 1 year.	Clinical success revealed 100% at 1 week follow-up examination. At 3 months, there was 1 failure in the CH group. At 6 months, there were 4 new failures (3 in the MTA group and 1 in the CH group). At 1 year, there was another failure in the CH group. There were no significant differences among the groups.	Calcium silicate materials appear to be suitable potential materials to replace CH. No significant differences were found between both studied materials. Biodentine and MTA were more advantageous than CH.	High risk of bias _Number and blindness of investigators were not reported. _Dropouts increase and evaluation period _Unreported interexaminer and intraexaminer calibration test.
Koc Vural, et al. [9]	To assess the efficacy of CH and MTA in the treatment of deep carious lesions by the complete caries removal technique.	A total of 100 permanent molar/premolar teeth were capped with either CH or MTA and restored with composite resin in 73 patients. Periapical radiographs were acquired prior to the treatment as well as at six, 12, and 24 months post-treatment. The clinical and radiographic evaluation was performed by Two calibrated examiners.	The success rate of the complete caries removal is 94% in both groups. Failure of four teeth capped with CH and two capped with MTA due to occurrence of irreversible pulpitis. There were no significant differences in pulp vitality between the bioactive materials at six, 12, or 24 months post-treatment ($p=0.238$, $p=0.606$, and $p=0.427$, respectively).	Both pulp-capping materials were found to be clinically acceptable at 24 months post-treatment.	High risk of bias _Simple randomization _Patients may receive more than one treatment. _Teeth created pulp exposure were excluded from the study. _No long term results. _No rubber dam isolation (saliva ejector and cotton roll only)
Kundzinz, et al. [10]	To compare the appropriateness of CH and MTA as direct "pulp capping materials" in permanent molars with carious pulpal exposure in adult.	A number of 70 adults aged 18–55 years were randomly distributed into two groups: CH and MTA. Followed up was performed after 1 week and at six, 12, 24 and 36 months on the basis of clinical and radiographic parameter. At each check-up, pulpal survival rates were tested by sensibility and periapical radiographs (excluding the radiographs taken at the 1-week follow-up).	At 3 years follow up, analysis showed a cumulative estimate rate of 52% for the CH group and 85% for the MTA group ($P = 0.006$). There was no significant effect between the capping material and postoperative pain.	Mineral trioxide aggregate performed potentially than a CH liner as a direct pulp capping material in molars with carious pulpal exposure in adult patients.	Moderate risk of bias One investigator only. Interexaminer and intraexaminer calibration test were not reported but assessment of all radiographs for periapical changes were performed in a separate blinded setting.

Chailer tvanitkul, et al. [11]	To differentiate between the treatment result using MTA and CH for partial pulpotomy in cariously exposed young permanent molars in a randomized clinical trial.	Eighty-four teeth in 80 children (aged 7–10 years) suffering from signs and symptoms of reversible pulpitis and having carious pulp exposures were randomly divided into two study arms; Dycal and ProRoot MTA. Vitremer was placed over the capping material until the remaining cavity was 2 mm in depth; finally amalgam was placed. Teeth were Mean survival times and incidence of extraction were calculated. evaluated clinically and radiographically after 24 h, 3 months, 6 months, 1 year and 2 years.	For both Dycal and ProRoot MTA groups, the median survival time was 24 months. Three teeth had unfavourable outcomes with the incidence rate of 0.11/100 tooth-months with Dycal (95% CI: 0.001–0.60) and 0.20/100 tooth-months with ProRoot MTA (95% CI: 0.02–0.71). The incidence of unfavourable results was 2.38/100 (95% CI: 0.29–8.34) and 0.05/100 (95% CI: 0.001–0.30) tooth-months in teeth with large (>5mm ²) and small (<5mm ²) pulp exposure areas, respectively.	Using either Dycal or, ProRoot MTA in partial pulpotomy young teeth for patients suffering from reversible pulpitis, resulted in favourable treatment outcomes for up to 2 years. Teeth with pulp exposure areas larger than 5 mm ² decreased the success rate of partial pulpotomy.	High risk of bias No sample size calculation. Interexaminer and intraexaminer calibration test were not reported
Cengiz, et al. [12]	To evaluate the efficacy of “erbium, chromium-doped: yttrium, scandium, gallium, and garnet laser irradiation “(Er,Cr:YSGG)” combined with CH and resin-based tricalcium silicate material in direct pulp capping for a 6-month follow-up period.	A total of 60 teeth of 60 patients between the ages of 18 and 41 years freeing of symptoms and radiographic changes were randomly assigned to the following 4 groups (n = 15): CH, laser- CH, TheraCal, and laser-TheraCal. Laser irradiation at an energy level of 0.5 W without water and with 45% air. When combination of laser with tested material Recall examinations were processed at the 1-week and 1-, 3-, and 6-month was done, irradiation with an Er,Cr:YSGG laser was performed followed by application of either CH or TheraCal.	The success rates in the TheraCal and CH groups were 66.6% and 73.3%, respectively. In both --laser-groups, success rates were 100%. The “Er,Cr:YSGG” laser-irradiated TheraCal and “Er,Cr:YSGG” laser--irradiated CH groups showed statistically higher success rates than the TheraCal and CH groups, respectively, while there was no significant difference between TheraCal and CH groups.	Combination of pulp capping agents and Er,Cr:YSGG laser irradiation at 0.5 W without water can be recommended for direct pulp therapy.	High risk of bias One investigator only. Short Follow up time (6 months)

Lee, et al. [13]	To compare the clinical outcomes of pulp exposed teeth treated with either poly (ϵ -caprolactone) fiber mesh as a scaffold for MTA (so-called PCL-FM/MTA) or MTA direct pulp capping.	Sixty human vital teeth were evenly divided into 4 groups (n = 15 in each group). Teeth in groups 1 and 2 were treated with PCL-FM/MTA direct pulp capping, and those in groups 3 and 4 were treated with MTA direct pulp capping. Teeth in groups 1 and 3 had pulp exposure <1 mm in diameter, whereas teeth in groups 2 and 4 had pulp exposure of 1–1.5 mm in diameter.	Teeth treated with PCL-FM/MTA direct pulp capping formed a thicker dentin bridge than teeth treated with MTA direct pulp capping three months later. Teeth with small pulp exposure (<1.0 mm in diameter) needed a shorter mean duration for dentin bridge formation than teeth with relatively larger pulp exposure of (1–1.5 mm in diameter) after Additionally, none of the teeth treated with PCL-FM/MTA as direct pulp capping showed tooth discoloration after treatment for 3 months.either PCL-FM/MTA or MTA direct pulp capping treatment.	Teeth treated with PCL-FM/MTA direct pulp capping needed a significantly shorter mean duration for dentin bridge formation than teeth treated with MTA direct pulp capping. PCL-FM/MTA is a better combination material than MTA alone for direct pulp capping of permanent teeth.	High risk of bias Short Follow up time (3 weeks) No sample size calculation. randomization was not reported ethical approval & signed informed consent
Asgary, et al. [14]	To evaluate clinically and radiographic the success of 4 VPTs (complete carious removal with protective dressing, direct pulp capping [DPC], miniature pulpotomy [MP], and full pulpotomy [FP]) using calcium-enriched mixture cement for deep caries management of mature permanent molars with clinical and radiographic changes indicative of Periodontitis.irreversible pulpitis with or without apical	Blinded participants (N = 302) were randomly allocated to 4 study arms. Random allocation was ignored when noticeable pulp exposures didn't occur after complete caries removal and the tooth was transferred to the IPC arm. Pre- and post-operative data including vitality test results, exposure type/location and pulpal/periapical status were recorded. Pain was measured using a numeric rating scale before treatment initiation up to 1 week post-operatively. Participants were followed up for 1 year	Teeth with reversible/irreversible pulpitis with or without apical periodontitis revealed 91% success rate with no significant difference in clinical/radiographic success rates regardless of "Vital pulp therapy" type. Preoperative pain was significantly different among the groups ($P < 0.05$) Treatment length (minutes) was significantly different among the groups ($P < .001$).	In deep caries management of mature permanent molars, the 4 VPTs were associated with favorable/comparable clinical and radiographic outcomes. Pulpal exposure type/location as well as the pulpal and periapical status had no effect on treatment outcomes.	High risk of bias Improper Randomization Unreported number of investigators Interexaminer and intraexaminer calibration test Isolation method was not reported. Non blinded investigators Increase droup out of patients at the follow up session which affected the outcome assessment.

Asgary, et al, [15]	To compare both clinical and radiographic results of pulpotomy in permanent molars with irreversible pulpitis using MTA or calcium enriched mixture (CEM) cement.	A total of 413 patients were randomly allocated into two study arms: CEM pulpotomy (PCEM: n = 205) and MTA pulpotomy (PMTA: n = 208). Numerical rating scale questionnaires were utilized by the patients to record pain intensity (PI) over 7 days post-operatively. The patients were followed-up for one year to assess the clinical and radiographic outcomes of treatment.	There was no significant difference in the mean (PI) recorded during the 7 post-operative days between the two materials (p = 0.221). The clinical and radiographic success percentage for PMTA at 12-month follow-up were 98 and 95% respectively; and for PCEM 97 and 92%, respectively. There was no significant differences in clinical (p = 0.7) and radiographic (p = 0.4) success rates between the two materials.	Excellent treatment outcomes occurred in permanent molar teeth with irreversible pulpitis subjecting pulpotomy with MTA and CEM biomaterials.	Moderate risk of bias No long term follow up.
---------------------	---	---	---	---	---

Table 1: The included clinical trial details about management of deep caries lesions.

Study	Sample Size	Sample size calculation	Type of teeth	Age (years)	pulp status	Method of caries removal	CT design	random ization	Treatment evaluated	Rubber dam Application	Types of material evaluated		Time between provisional and permanent	permanent filling	Obtaining Ethical approval& Signed Informed consent	No. of Investigators	Blindness of the investigator	Inter examiner and intra examiner calibration test	Assessment criteria	Follow-up (months)
Bjorndal, et al. [4]	314 individuals	y	Any tooth	18-49 y or ≥50 y	No signs of irreversible pulpitis (mild pain could be present) Carious lesions involved ≥75% of the dentin	Hand instrument	2 parallel groups	y	incomplete carious removal and SW	y	complete caries removal + CH cement direct pulp capping	SWE using CH cement Partial pulpotomy	stepwise : incomplete excavation then application of CH for 8- 12 wk then temporarily sealed with GIC, the cavity was reentered and incomplete carious removal to hard dentin was performed . incomplete carious removal :no provisional restoration	RC	Y & y	2	y	Y & y	clinical + radiographic	Till 60 months follow-up (median 16 months)

Maltz, et al. [16]	299	y	molar	17.17 ± 10.9	No signs of irreversible pulpitis Carious lesions involved 50% of the dentin	hand excavators and/or low-speed metal burs	parallel	y	SWE and PCR	y	SW using CH cement	PCR using CH cement	SWE: CH cement then modified zinc oxide-eugenol cement (IRM) for 90 days PCR: no provisional restoration	GIC then amalgam or CR	Y&y	1	y	y	clinical + radiographic	18,36 and 60 months
Pereira, et al. [2]	98 patients	y	posterior teeth	15 to 30	No signs of irreversible pulpitis Carious lesions involved ≥75% of the dentin	Excavator	Parallel group	y	SWE	y	SWE using RMGI and hydroxide liner	SWE using RMGI without hydroxide liner	CH liner (control group) or without a CH liner (test group) then provisionally restored with RMGI for 90 days	RC	Y & Y	1	y	y	dentinal, radiographic+ microbiological criteria	3 months
Durmus, et al. [3]	105	y	molars	Jun-13	No signs of irreversible pulpitis Carious lesions involved ≥75% of the dentin	No.16 round carbide bur	parallel	y	SWE	y	NO disinfectant	ozone, or chlorhexidine	Ozone :exposed to gaseous ozone for 60 s, 2% chlorhexidine digluconate application for 60 s using a brush. Then application of CH then GIC for 4 months then reopening and complete removal of demineralized dentine	GI then RC	Y&Y	1 investigator+1 microbiologist	Y	NR	clinical + radiographic + microbiological analyses	4
Parinyaprom, et al. [4]	59	Y	NR	Jun-18	reversible pulpitis, or irreversible pulpitis, early periapical involvement Carious lesions involved ≥75% of the dentin	low-speed round steel bur and a spoon excavator	parallel	y	Complete caries removal + Direct pulp capping	y	Mineral trioxide aggregate (MTA)	Calcium silicate based (Biodentine)	1.5-mm of ProRoot MTA is covered by resin-modified glass ionomer cement Biodentine was placed as a pulp dressing and a base material then allowed to set in 12 minutes.	RC(70.9%, amalgam(1.8), or SSC (27.3) depending on the amount of tooth structure left.	Y & Y	5	Y	Y&Y	clinical + radiographic	6-54 months

Uesrichai, et al. [5]	69	y	molars	Jun-18	irreversible pulpitis	slow-speed round steel bur and an excavator	parallel	y	Partial pulpotomy	y	Mineral trioxide aggregate (MTA)	Calcium silicate based (Biodentine)	No provisional restoration RMGI placed immediately over the MTA layer then permanent restoration Biodentin :wait 12 min for application of permanent restoration	RC or SSC	Y&y	2 +1 radiographic	y	Y&y	clinical + radiographic	Every 6 months up to 72 months
Lama Awawdeh, et al. [6]	68	y	both anteriors and posteriors	16-59	No signs of irreversible pulpitis or periapical lesions	round diamond burs, ISO no. 23 (at high speed under air-spray coolant.	parallel design	y	direct pulp capping or pulpotomy	y	Mineral trioxide aggregate (MTA)	Calcium silicate based (Biodentine)	Biodentin was placed and allowed to set within 12 minutes then temporized with Intermediate Restorative Material (IRM) MTA:A moist cotton pellet was placed over the it, and the tooth was temporized with IRM	Amalgum (22.0%)or RC (77.9%)	Y+Y	1	Y	NO	clinical + radiographic	6,12, 24, and 36 months
Katge, et al. [7]	29 patients with 58 teeth	y	bilateral first molars	07-Sep	No signs of irreversible pulpitis or periapical lesions Carious lesions approaching the pulp	sharp no. 130 spoon excavator	split mouth study	y	Complete caries removal + Direct pulp capping	y	MTA	Biodentin	Biodentine was filled in the entire cavity for 3 months. MTA is covered by RMGI for 3 months	Biodentine :RC over biodentin MTA: RC over RMGI	Y&y	NR	NR	NR	Clinical (vitality test by electrical pulp tester) + radiographic	6 and 12 months
Brizuela, et al. [8]	169 patients	y	Mature or immature molars	Jul-16	No signs of irreversible pulpitis or periapical lesions	round bur (low speed handpiece) and spoon excavator + caries detector dye	parallel	y	Complete caries removal + Direct Pulp Capping	y	CH	Biodentine white ProRoot MTA	No provisional restoration	RMGI then direct resin restoration	Y &y	NR	NR	NR	Clinical+ Radiographic	1week, 3, 6, and 12 months

Koc Vura I, [9]	100	y	posteriors	20± 3.48	No signs of irreversible pulpitis Carious lesions involved ≥75% of the dentin	Wide sharp spoon excavators + steel bur, applied at a low speed	parallel	y	complete carious removal + protective dressing placement	No	CH (Dycal)	MTA	No provisional restoration	RMGI then composite resin (Sandwich technique material)	Y & Y	2	y	Y&y	clinical + radiographic	6, 12, and 24 months
Kundzina, et al. [10]	70	y	molars	18–55	No signs of irreversible pulpitis; attachment loss not exceeding 4 mm; Carious lesions involved ≥75% of the dentin	hand excavator + caries detector dye	parallel	y	Direct pulp capping	y	CH (Dycal)	MTA	The teeth were temporized for 1 week with GIC	MTA group: RC alone /CH group: GIC then RC	Y & Y	1	y	NR	clinical + radiographic	1 week, 6, 12, 24, 48 and 36 months
Chailertvanitkul, et al. [11]	84 teeth (patients=80)	NR	molars	7–10	reversible pulpitis	A large round bur in a low-speed handpiece and spoon excavators	parallel	y	partial pulpotomies	y	calcium hydroxide	mineral trioxide aggregate	Light-cured Vitremer cover the capping material	amalgam	y&y	2	y	NR	clinical + radiographic	24 h, 3,6,12,24 months
Cengiz, et al. [12]	60 teeth	y	38 premolars and 22 molars	18 - 41	Normal pulp	NR	parallel	y	Direct pulp capping	y		CH paste Er,Cr:YSGG laser-+CH paste TheraCal LC Er,Cr:YSGG --laser- +TheraCal LC	No provisional restoration	RMGI then RC (sandwich technique)	Y&Y	1	y	y	Clinical + radiograph	1 week and at 1, 3, and 6 months

Lee, et al. [13]	60	NR	both anteriors and posteriors	Dec-68	Normal pulp	spoon excavator and then a low-speed handpiece with a 0.8-mm round bur	parallel	NR	Direct pulp capping	y	.MTA alone	Electrospun Poly (ε-caprolactone) Fiber Meshes / MTA (PCL-FM/MTA)	sealed with Caviton for one day	direct resin filling	NR	2	y	Y&y	Clinical + radiographic	3 months
Asgary, et al. [15]	413	y	molars	9-65	irreversible pulpitis	a large sterile round-end bur in a high-speed	parallel	y	pulpotomy	y	MTA	CEM	the cavity sealed temporarily with Cavit for 7 days.	amalgum	Y&y	4 +2 radiologists	y	Y&y	clinical +radiographic	1 day, 1 week and then 12 months
Asgary, et al. [14]	302	y	Molar	28±10	reversible/ irreversible pulpitis with or without apical periodontitis	round-end sterile diamond burhigh speed with very low pressure	parallel	y	4 VPTs : complete carious removal with protective dressing placement,direct, pulp capping (DPC), miniature Pulpotomy (MP), and full pulpotomy (FP)	NR	complete carious removal +protective dressing placement using Calcium phosphate based cement (CEM cement) calcium enriched mixture	DPC, MP, and FP using Calcium phosphate based cement (CEM cement) calcium enriched mixture	2-3 mm thickness of CEM then Covered by RMGI	RC (sandwich tech.)	Y & Y	NR	No	NR	clinical + radiographic	3- and 12 months

Table 2: Evaluation of the methodologies used in the reviewed clinical trials.

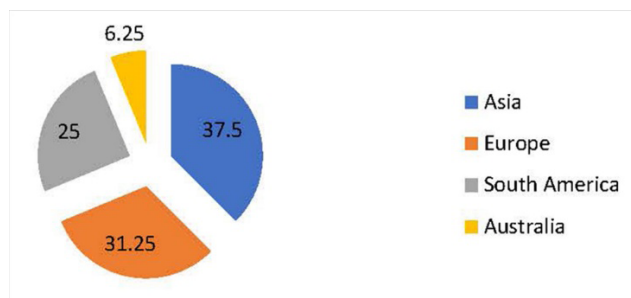


Figure 2: Geographic distribution of the selected clinical trials.

The objectives, methodology, results, and conclusions of the clinical trials are summarized and assessed in Table 1. The methodology of each CT was evaluated using different criteria, including technique name, randomization, study design, sample size, rubber dam application, subject types, ethical-related issues, type of study blindness, performance of an intraexaminer and extra-examiner calibration test, evaluation type, and follow-up term (Table 2).

This systematic review included 16 randomized clinical trials, with unclear data about randomization in one clinical trial [8]. With the exception of one split mouth design [9], the study design of the trials was parallel. Sample size was calculated for the majority of the clinical trials, and only two studies did not report data about calculation of sample size [8,10].

All clinical trials included participants with deep caries and in need of extensive restorative procedures with exposure or near-exposure of the dental pulp that invariably resulted in pulp inflammation as either reversible or irreversible pulpitis. The major clinical trials presented VPT with no signs of irreversible pulpitis or periapical lesions, while 4 articles revealed irreversible pulpitis with or without early periapical involvement [1,3,11,12], in addition to one randomized control trial (RCT) that revealed mild preoperative pain [4].

Patients in the majority of clinical trials were young and/or adults, except five trials including older patients [4,6,8,11,13]. The majority of the clinical trials included in this analysis followed the complete caries removal technique. Four clinical trials depended on incomplete caries removal techniques, either 1 step caries removal (partial excavation) [17] or two step caries removal (stepwise excavation) [4,17-19]. Eight trials used direct pulp capping, 6 trials used pulpotomy [20], and one randomized clinical trial compared the differences

between 4 VPT techniques [3].

Rubber dam isolation was used in 14 clinical studies, whereas one study used partial isolation only [14], and the other 1 did not mention the type of isolation [3]. Deep caries on the pulpal floor was removed using hand excavators and/or low-speed carbide burs. The included pulp capping materials were CH, CSCs, MTA, and its modifications, Biodentin, CEM, and resin-based tricalcium silicate (Theracal). The use of a laser (Er,Cr:YSGG laser) with pulp capping materials was studied in one clinical trial [16].

The included provisional restorations were glass ionomer cement in three clinical trials, resin-modified glass ionomer in five clinical trials, zinc oxide cement in six clinical trials, polymer reinforced zinc oxide eugenol cement (IRM) in four trials, zinc oxide/calcium sulfate (cavit) in one trial, and eugenol-free material (Cavition) in one trial, while 2 clinical trials did not use provisional restorations.

The permanent restorations used in the included clinical trials were resin composite restoration, amalgam, or stainless steel crown according to the amount of tooth structure left. Expensive extracoronary restorations such as inlay, onlay, and crowns were not added until 3 months after VPT [21].

The trials included in this analysis had ethical approval and signed informed consent except one clinical trial. This trial did not report any ethical approval [8]. Assessment criteria of all clinical trials included the clinical and radiographic evaluations and the microbiological assessment, which was added in two trials [18,19].

Long-term clinical follow-up (≥ 5 years) was performed in only three clinical trials (17.6%) [1,4,17] fulfilling the search criteria. Nine clinical trials published the moderate-term clinical follow-up (≥ 1 years) (58.8%) [21,22], while 4 clinical trials published only the immediate short-term outcomes (23.5%). The number of investigators used was in the range of 1 to 6. There were unreported data in three clinical trials [3,9,15]. The interexaminer and intraexaminer calibration test were used in seven clinical trials.

Regarding the blindness of participants, personnel, and outcome assessors (performance bias), the clinical practitioners could not be blinded in all clinical trials because the capping materials were different in terms of appearance and handling characteristics. Hence, the assignment was blinded only to the patients (single-blinded) and investigators in the majority of clinical trials.

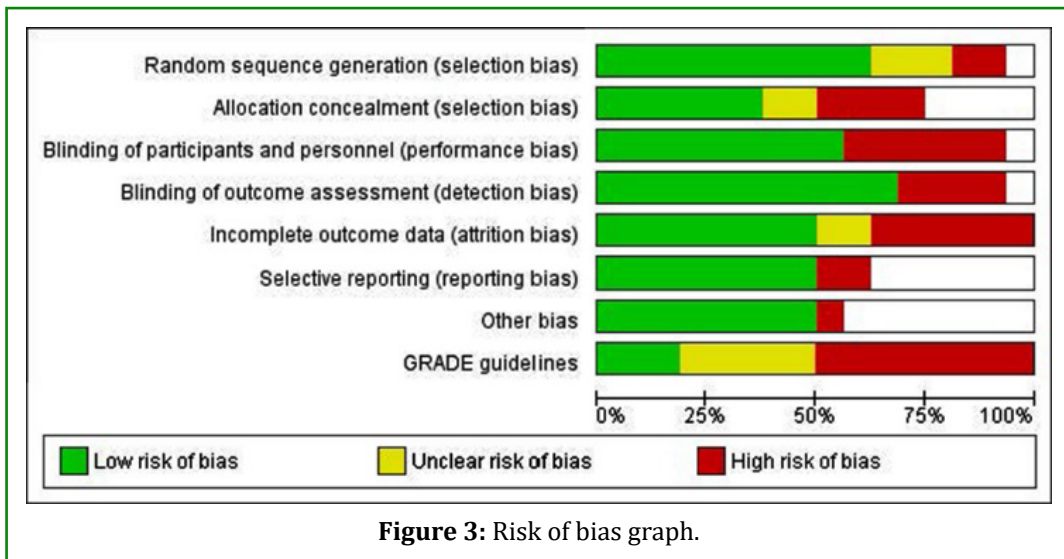


Figure 3: Risk of bias graph.

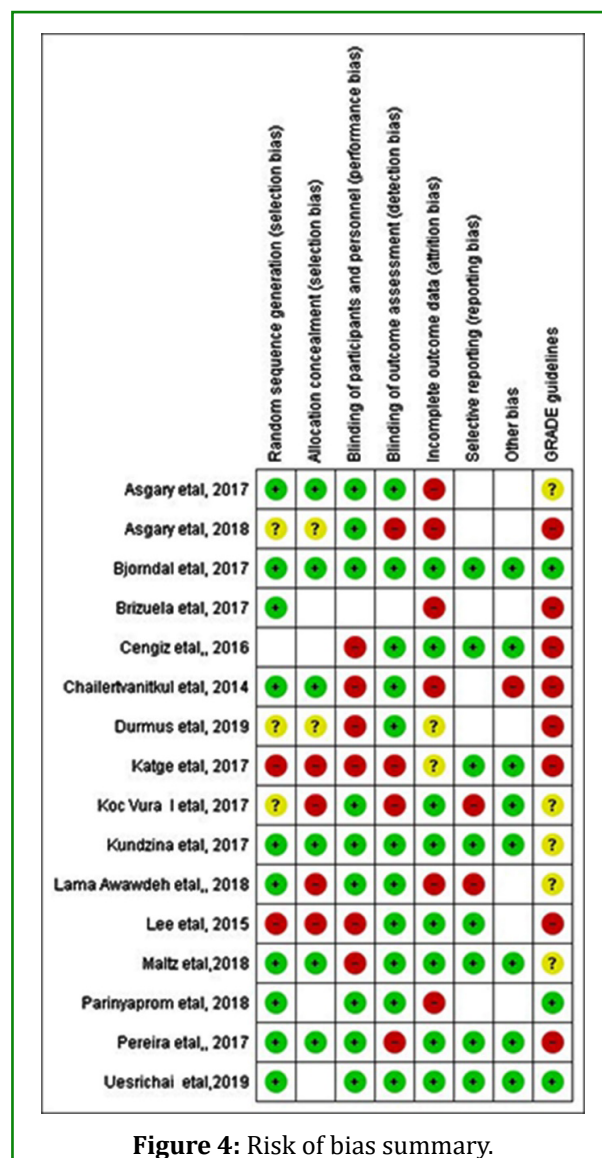


Figure 4: Risk of bias summary.

The risk of bias of the included articles is demonstrated in Figures 2 & 3 according to Cochrane collaboration's tool for assessing risk of bias and GRADE levels [20], which revealed nine studies with high risk of bias, 4 studies with moderate risk, and three studies with low risk. A risk of bias graph presented as percentages across all included studies is shown in Figure 3. A review of authors' judgments about each risk of bias item for each included study is included in the risk of bias summary (Figure 4). All domains were scored as (1) low

risk of bias, (2) unclear, and (3) high risk of bias [23].

This systematic review included 16 clinical trials that reported about different VPT techniques and several pulp capping materials. An illustrative diagram in Figure 5 shows how the included studies in this systematic review compared different pulp capping materials using circles containing the number of patients receiving this type of material, taking into consideration the different VPT used in each study.

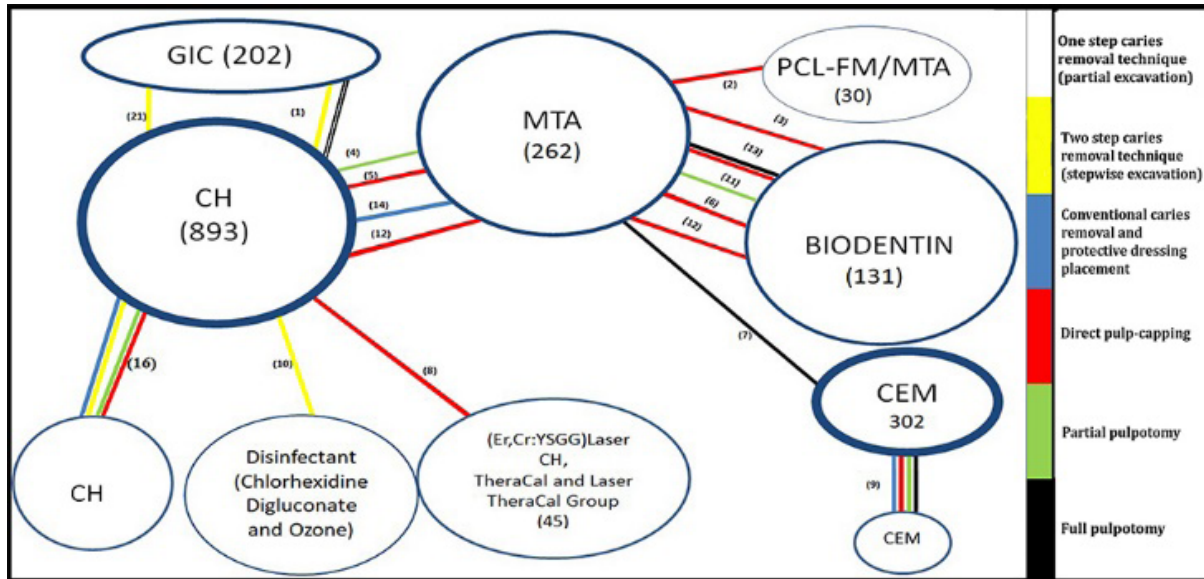


Figure 5: Illustrative diagram indicating comparison between pulp capping materials in the included studies. Different colors indicated different techniques of vital pulp therapy. White: 1-step caries removal technique (partial excavation); yellow: 2-step caries removal technique (stepwise excavation); blue: conventional caries removal and protective dressing placement; red: direct pulp capping; green: partial pulpotomy; black: full pulpotomy.

Regarding the illustrative diagram, there were 5 RCTs performed on Biodentine and MTA as pulp capping materials in different VPTs, therefore, these RCTs were included in the meta-analysis to evaluate their clinical performance. These studies had different risks of bias: 2 low risk of bias [1,12], 2

high risk of bias [9,15], and one moderate risk of bias [13]. The comparison of the success rate between MTA and calcium-silicate based (Biodentine) in five studies Chailertvanitkul P, et al. [10,13,14,16,21] is presented by forest plots (Figure 6).

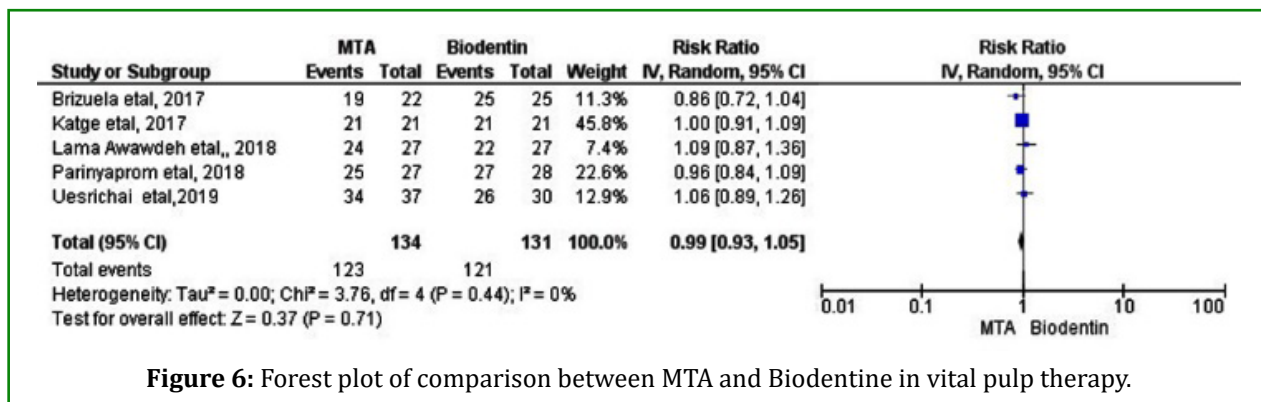


Figure 6: Forest plot of comparison between MTA and Biodentine in vital pulp therapy.

Pooled studies were homogenous ($P = 0.44$, $I^2 = 0\%$) so the data were analyzed by fixed model. The overall success rate between the MTA and Biodentine groups did not favor either of the two groups (RR, 0.99; 95% confidence interval from 0.93 to 1.05, $P = 0.71$). The remaining clinical trials were not included in the meta-analysis because these trials had heterogeneous methodology.

Discussion

As long as there has been growing clinical evidence supporting the suitability of various caries removal techniques and VPT, an updated systematic review and meta-analysis has been required. The result of treatment (the effect measure) is identified by determining that healing of either pulp or periapical tissue has occurred. For pulp capping or partial pulpotomy, the tooth should be asymptomatic with positive response to sensitivity testing in addition to absence of radiographic change of periapical conditions. Generally, the success of VPT can be achieved by both conserving defense mechanisms and preserving the vitality of the pulp.

Systematic review, by dint of the most reliable technique used to collect information, provides a fixed base for clinical decision making. It is a systematic assessment of the available literature for the effects of health care interventions and is an evaluation that is expected to help professionals in choosing the proper treatment.

All RCTs were conducted from 2009 to 2019. Participants were free from systemic diseases (e.g., no pregnancy nor any systemic disease preventing enrolment) and had normal pulp or reversible/irreversible pulpitis with or without apical periodontitis, and the studies included patients of all ages. Intervention included complete and incomplete caries removal including 1- or 2-step technique, direct pulp capping, partial pulpotomy, pulpotomy and pulpectomy, and various pulp capping materials. Exclusion criteria were animal studies, experimental studies, human teeth employing necrotic pulps or with traumatic pulp exposure, retrospective studies, deciduous teeth, pulp dressings that devitalized pulpal tissue, prospective observational studies without reference groups, and studies with small sample size.

Studies with small sample sizes tend to be less reliable and are more probably inconclusive due to inadequate statistical power [24]. In addition, study designs based on using traumatic teeth were excluded because the pulp responds differently in traumatic and pathologic pulp exposures even at the molecular level, with different molecular interactions that potentially affect the final outcome [25]. The major causes of postoperative inflammation and pulp necrosis are non-sterile procedures and bacterial micro-infiltration of the

pulp through dentin tubules that occurs with pathologic pulp exposure [26].

Studies including primary or mixed dentition were excluded because there are some differences between primary and permanent teeth. When the sizes of teeth are compared, the enamel and dentin layers of primary teeth are thinner, the primary teeth pulp is closer to the enamel layer, and the primary teeth pulp is wider. These factors lead to easy pulpal perforation in primary teeth with very deep caries. Besides, the deciduous teeth could not provide the opportunity for long-term follow-up due to their normal physiological resorption and shedding in addition to the possibility of internal resorption and perforation due to the thinness of primary molar teeth [27].

There were substantial gaps in our knowledge base with respect to treatment of the vital pulp exposed to deep carious lesions. Therefore, this study is able to offer a clear answer to the question of whether stepwise excavation and partial caries removal are more successful methods for deep carious lesions than complete caries removal techniques, in addition to evaluating the success of VPT, including direct pulp capping, partial pulpotomy and pulpotomy. Furthermore, it was unclear whether leaving more carious dentin may be beneficial (fewer pulp exposures and symptoms) or detrimental (higher risk of failure and caries progression). Moreover, this systematic review compared the included clinical trials to reveal the pulp capping materials that were effective in producing ideal or intended results.

Several studies followed the conventional caries removal technique that leads to increased risk of pulp exposure with deep lesions, which is considered the worst scenario that practitioners can be faced with, and the outcome is more unpredictable. On the other hand, four studies Bjørndal L, et al. [4,17-19] ensured the efficacy of incomplete caries removal techniques, either 1 step caries removal (partial excavation) or two step caries removal (stepwise excavation), which depend on an intimate coronal seal leading to reduction of bacterial number and activity. Consequently, the clinical free signs and symptoms, microbiological signs of caries inactivation, and radiographical signs of dentin remineralization Schwendicke F, et al. [28] supported the success of these methods, which was in agreement with the results of other systematic reviews [20,28].

Regarding studies of incomplete caries removal, except for one study with low risk of bias [4] and one study with moderate risk of bias [17], the remaining two studies showed high risk of bias [18,19]. The cause of the high risk of bias was that follow-up times were not long enough to enable recording any difference in pulpal symptoms and restoration failures over time. In addition to noncompliance or missing

outcomes need potential statistical solutions to solve this problem as intention-to-treat analysis studied by Gupta, et al. [29]. The number and blindness of investigators and results of the inter- and intraexaminer calibration tests were not reported.

Two studies reported that the stepwise carious removal group (SW) had a significantly higher proportion of persistent pulp vitality without apical radiolucency versus incomplete carious removal of deep carious lesions in adult teeth at 5-year follow-up [4,17]. Maltz, et al. [17] registered a lower exposure rate and a higher success rate in the stepwise carious removal group than Bjørndal, et al. [4]. This difference between Bjørndal et al. and Maltz et al may be caused by four things. First, the eligibility criteria of the first study included older patients (more than 50 years) while some clinical studies revealed that elderly patients had a decreased chance for pulp healing because the vascularity of the pulp diminishes with age with increased pulpal calcification [30,31].

Secondly, the preoperative radiographical examination of carious lesions in the Bjørndal study showed involvement of more than or equal to three-fourths of the dentin thickness, while in the Maltz et al study, the radiographic examination of the carious lesions was restricted to only half the dentine thickness. Third, the presence of mild preoperative pain among a large patient number in the first study described the pulp inflammation.

The fourth reason was related to the careful removal of remaining carious dentine in the Maltz et al study, as in the second visit of the excavation trial when there were still active caries characteristics that increased the risk of pulp exposure during the final excavation, and a new temporary filling was placed for more than 30 days before reopening and final excavation. However, it should be remembered that Bjørndal et al had low risk of bias while Maltz, et al. [17] had a moderate risk of bias (1 investigator only and patients may receive more than one treatment).

Another study with high risk of bias Pereira MA, et al. [19] revealed that there was no significant difference whether CH liner was added during stepwise excavation or not, but this study had a short follow-up time, and therefore other data may be missing about pulp status overtime. Another recent study Durmus N, et al. [18] revealed that using cavity disinfectant as chlorhexidine digluconate in the stepwise excavation yielded successful results in reducing the number of microorganisms and arresting decay. The technique of deep caries removal, age of the patient, and pulp status tended to influence the treatment results.

In young patients, 1-step incompletely excavated teeth

followed by 2-step excavated teeth, without preoperative symptoms, and the presence of half or more remaining dentine thickness on radiographic examination showed reduced risk of pulp exposure during management of deep carious lesions, compared to completely excavated teeth with the presence of preoperative pain, the presence of extensive deep caries invading $\geq 75\%$ of dentin thickness, or old age.

Five studies (31%) of the included studies were incorporated in the meta-analysis to evaluate the clinical performance of Biodentine and MTA as pulp capping materials in different VPTs. Awawdeh L, et al. [13] these studies had two low risk of bias, 2 high risk of bias [9,15], and one moderate risk of bias due to unreported number and blindness of investigators because there was an unclear difference between the two materials radiographically; MTA was more radiopaque than Biodentine, which made investigator blinding difficult. Besides this there was the number of dropouts and the short length of the evaluation period, the inter- and intraexaminer calibration tests were not reported, and treatment was given for more than one tooth per patient.

The formation of the dentin bridge of calcium silicate materials (MTA, Biodentine) is not completely understood [32]. These materials discharge CH as a by-product; however, dissimilar to pure CH, which dissolves over time, CSMs are relatively stable, promote dentin bridging, and are probably able to seal the injured pulpal tissue [32,33]. The inflammation that is induced by these materials is only short-term, less severe, and less extensive than that induced by CH [34]. The similarity of the tissue response with MTA and Biodentine may be due to their similar chemical compositions (tricalcium silicate), the by-product released during the setting reaction [35] and physical properties [36].

Four studies Brizuela C, et al. [15] in the systematic review evaluated the efficacy of MTA and CH in different VPTs. However, these studies were not included in the meta-analysis because the quality of available studies was low and the studies with high risk of bias were contradictory. One study had moderate risk of bias [6], while the other 3 studies had high risk of bias due to unreported or an insufficient number of investigators, in addition to unreported blindness, inter- and intraexaminer calibration tests, the short length of the evaluation period, or an increase in patient dropouts. In one of the previously mentioned studies Koc Vural U, et al. [14] the high risk of bias was related to simple randomization, patients who received more than one treatment, teeth that developed pulp exposure that were excluded from the study, and no rubber dam isolation.

One study with moderate risk of bias due to a single investigator, no information about inter- and intraexaminer calibration tests, and the fact that all radiographs were

assessed for periapical changes in a separate, blinded setting, revealed that mineral trioxide aggregate performed more effectively than CH liner as a direct pulp capping material in molars with carious pulpal exposure in adult patients. However, this study reported high failure rate in two groups, which may be related to the lack of a periapical radiograph at baseline. This may have adversely affected the overall success in both groups and may be related to older patients who have reduced pulp response, thus they were at a high risk of developing irreversible pulpitis or necrosis.

Otherwise, three studies Chailertvanitkul P, et al. [10,14] with high risk of bias showed no significant difference between CH and MTA. The first study Koc Vural U, et al. [14] reported the equal results by complete carious removal followed by protective dressing placement of MTA or CH. This study had high risk of bias because of simple randomization, exclusion of the teeth from the study when pulp exposure occurred, patients who may have received more than one treatment, no rubber dam isolation, and short-term results. Therefore, the low quality of the study affected the study confidence. In addition to the evidence of ion exchange between these materials and dentin at a chemical level, the evidence to support interfibrillar or intrafibrillar remineralization of the carious dentin is weak [37,38]. Also, the significant thickness of radiopaque dentin under carious lesions at baseline (on average, greater than 1.5 millimeters) weakened any effect of the pulp capping materials.

Another study Brizuela C, et al. [15] reported no significant differences among the materials when used in direct pulp capping. This study had high risk of bias due to number, blindness, the inter- and intraexaminer calibration tests of investigators not being reported, increased dropouts, and the short length of the evaluation period, which may lead to missing data, in addition to the young age of participants that increased the success rate of all groups. Furthermore, the failed MTA-pulp capping cases may refer to immediate application of final restoration over unset MTA, which may release toxic components that cause a limited zone of pulp tissue necrosis at the MTA-pulp tissue interface without respecting the setting time of MTA, which is approximately 2 h and 45 min [39].

The third study Chailertvanitkul P, et al. [10] showed no significant difference between the materials when used in partial pulpotomies. This study had high risk of bias due to unreported inter- and intraexaminer calibration tests and absence of sample size calculation, which adversely affected the confidence of the results, besides the patients' young ages, which may have played a great role in the rapid pulp healing of both MTA and CH groups [10].

One study Lee LW, et al. [8] used electrospun poly

(ϵ -caprolactone) fiber meshes in combination with mineral trioxide aggregate direct pulp capping (PCL-FM/MTA) to enhance results of MTA, thus acting as a barrier for tissue engineering [40]. This PCL fibrous engineered matrix imitates the architecture of the natural extracellular matrix that can modulate the cell responses, prompting tissue regeneration [41]. Therefore, another study Cengiz E, et al. [16] enhanced the success rate of direct pulp capping by using Er,Cr:YSGG laser irradiation at 0.5 W without water in combination with CH and Theracal because of the biostimulation, hemostatic, and coagulant effects [42-44].

There was a study Asgary S, et al. [3] comparing the effect of calcium-enriched mixture cement after complete caries removal with protective dressing placement, direct pulp capping, miniature pulpotomy, and full pulpotomy for deep caries management of mature permanent molars, including teeth with clinical signs of irreversible pulpitis with or without presence of apical periodontitis. The study revealed a high success rate with no significant difference in clinical/radiographic success rates regardless of the type of intervention (i.e., VPT techniques).

This study had a high risk of bias because randomization was ignored once the exposure occurred during deep caries removal, depending on ethical concerns. Thus, the tooth was automatically transferred to the least invasive technique group (complete caries removal with protective dressing placement). There were no data about number, blindness of investigators, inter- or intraexaminer calibration tests, or the increased dropout of patients at the follow-up session, which affected the outcome assessment. Another study with moderate risk of bias Asgary S, et al. [11] revealed a high success rate of partial pulpotomy in mature permanent molars with irreversible pulpitis with two biomaterials, MTA and CEM, which did not have different results. This study didn't describe the radiographic assessment at baseline, however, all the failed cases were associated with a radiographic lesion. In addition, this study did not provide long-term follow-up, which may lead to missing data.

Limitations of this systematic review included studies with short-term trials, higher heterogeneity represented by case selection, different steps, various materials, different re-entry times, diverse population of participants, different outcome criteria (clinical, radiographic, and/or microbiological studies), and different risk of bias. Further calibrated, multi-centered randomized studies with high quality are recommended. Within the limitations of the existing clinical trials, the outcomes of the present study show that the Biodentine had a similar effect to MTA in VPT.

The included studies provided the improvement success results of incomplete caries removal compared with

conventional caries removal. Based on sub-analyses of influencing factors, 1-step incompletely excavated teeth, without pulpal inflammation in young patients enhanced the success rate. The degree of pulp inflammation can be assessed by the presence, absence, or persistence of preoperative signs and symptoms, clinical examination by a sensitivity test, the extent of caries, and remaining dentin thickness. Therefore, pulp inflammation may lead to failure of the incomplete caries removal technique and the occurrence of irreversible pulpitis and necrosis [17-19].

The success of direct pulp capping depends on patient age, stage of root development [45] and size of exposure. Healthy pulp with an uncompromized blood supply at the time of capping is essential for successful VPT. The evaluation criteria for successful VPT are not limited to clinical signs and symptoms [46] but it also extend to pulpal bleeding, which is a clinical indicator of pulpal inflammation [47,48] and the capacity of restorative materials to provide coronal seal.

Conclusions

Based on moderate quality studies, this study reported that available calcium-silicate based cements are biocompatible and can stimulate dentin bridge formation with a low inflammatory response. No CSC was clearly superior to alternatives. A combination of preoperative symptoms and clinical observations (including the absence, presence, persistence, and character of pain; the extent and depth of the pulp exposure; and the pulp's size and tendency to bleed) could be employed to form an educated decision regarding the VPT procedure to implement. Incomplete caries removal techniques reported higher success rates than the complete caries removal technique. The technique of deep caries removal, age of the patient, and lack of any pulpal inflammation tended to influence the treatment results. Direct pulp-capped teeth with opened apex, pin point exposure with no pulpal inflammation, and well-sealed coronal restoration in young patients showed higher success in pulp healing.

References

1. Uesrichai N, Nirunsittirat A, Chuveera P, Srisuwan T, Sastraruji T, et al. (2019) Partial pulpotomy with two bioactive cements in permanent teeth of 6- to 18-year-old patients with signs and symptoms indicative of irreversible pulpitis: a noninferiority randomized controlled trial. *International endodontic journal* 52(6): 749-759.
2. Ghoddusi J, Forghani M, Parisay I (2014) New approaches in vital pulp therapy in permanent teeth. *Iran Endod J* 9(1): 15-22.
3. Asgary S, Hassanizadeh R, Torabzadeh H, Eghbal MJ (2018) Treatment Outcomes of 4 Vital. Pulp Therapies in Mature Molars. *Journal of endodontics* 44(4): 529-535.
4. Bjorndal L, Fransson H, Bruun G, Markvart M, Kjaeldgaard M, et al. (2017) Randomized Clinical Trials on Deep Carious Lesions: 5-Year Follow-up. *Journal of dental research* 96(7): 747-753.
5. Asgary S, Nazarian H, Khojasteh A, Shokouhinejad N (2014) Gene expression and cytokine release during odontogenic differentiation of human dental pulp stem cells induced by 2 endodontic biomaterials. *Journal of endodontics* 40(3): 387-392.
6. Kundzina R, Stangvaltaite L, Eriksen HM, Kerosuo E (2017) Capping carious. exposures in adults: a randomized controlled trial investigating mineral trioxide aggregate versus calcium hydroxide. *International endodontic journal* 50(10): 924-932.
7. Petrou MA, Alhamoui FA, Welk A, Altarabulsi MB, Alkilzy M, et al. (2014) A randomized clinical trial on the use of medical Portland cement, MTA and calcium hydroxide in indirect pulp treatment. *Clinical oral investigations* 18(5): 1383-1389.
8. Lee LW, Hsiao SH, Hung WC, Lin YH, Chen PY, et al. (2015) Clinicals outcomes for teeth treated with electrospun poly(epsilon-caprolactone) fiber meshes/mineral trioxide aggregate direct pulp capping. *Journal of endodontics* 41(5): 628-636.
9. Katge FA, Patil DP (2017) Comparative Analysis of 2 Calcium Silicate-based Cements (Biodentine and Mineral Trioxide Aggregate) as Direct Pulp-capping Agent in Young Permanent Molars: A Split Mouth Study. *Journal of endodontics* 43(4): 507-513.
10. Chailertvanitkul P, Paphangkorakit J, Sooksantisakoonchai N, Pumas N, Pairojamornyoot W, et al. (2014) Randomized control trial comparing calcium hydroxide and mineral trioxide aggregate for partial pulpotomies in cariously exposed pulps of permanent molars. *International endodontic journal* 47(9): 835-842.
11. Asgary S, Eghbal MJ, Bagheban AA (2017) Long-term outcomes of pulpotomy in permanent teeth with irreversible pulpitis: A multi-center randomized controlled trial. *American journal of dentistry* 30(3): 151-155.
12. Parinyaprom N, Nirunsittirat A, Chuveera P, Na Lampang

- S, Srisuwan T, et al. (2018) Outcomes of Direct Pulp Capping by Using Either ProRoot Mineral Trioxide Aggregate or Biodentine in Permanent Teeth with Carious. Pulp Exposure in 6- to 18-Year-Old Patients: A Randomized Controlled Trial. *Journal of endodontics* 44(3): 341-348.
13. Awawdeh L, Al-Qudah A, Hamouri H, Chakra RJ (2018) Outcomes of Vital Pulp Therapy Using Mineral Trioxide Aggregate or Biodentine: A Prospective Randomized Clinicals Trial. *Journal of endodontics* 44(11): 1603-1609.
 14. Koc Vural U, Kiremitci A, Gokalp S (2017) Randomized Clinicals Trial to Evaluate MTA Indirect Pulp Capping in Deep Caries. Lesions After 24-Months. *Operative dentistry* 42(5): 470-477.
 15. Brizuela C, Ormeño A, Cabrera C, Cabezas R, Silva CI, et al. (2017) Direct Pulp Capping with Calcium Hydroxide, Mineral Trioxide Aggregate, and Biodentine in Permanent Young Teeth with Caries.: A Randomized Clinicals Trial. *Journal of endodontics* 43(11): 1776-1780.
 16. Cengiz E, Yilmaz HG (2016) Efficacy of Erbium, Chromium-doped:Yttrium, Scandium, Gallium, and Garnet Laser Irradiation Combined with Resin-based Tricalcium Silicate and Calcium Hydroxide on Direct Pulp Capping: A Randomized Clinicals Trial. *Journal of endodontics* 42(3): 351-355.
 17. Maltz M, Koppe B, Jardim JJ, Alves LS, de Paula LM, et al. (2018) Partial caries removal in deep caries lesions: a 5-year multicenter randomized controlled trial. *Clinical oral investigations* 22(3): 1337-1343.
 18. Durmus N, Tok YT, Kaya S, Akcay M (2019) Effectiveness of the ozone application in two-visit indirect pulp therapy of permanent molars with deep carious lesion: a randomized clinical trial. *Clinical oral investigations* pp: 1-11.
 19. Pereira MA, Santos-Junior RBD, Tavares JA, Oliveira AH, Leal PC, et al. (2017) No additional benefit of using a calcium hydroxide liner during stepwise caries removal: A randomized clinical trial. *Journal of the American Dental Association* 148(6): 369-376.
 20. Bergenholtz G, Axelsson S, Davidson T, Frisk F, Hakeberg M, et al. (2013) Treatment of pulps in teeth affected by deep caries - A systematic reviews of the literature. *Singapore dental journal* 34(1): 1-12.
 21. Kang CM, Sun Y, Song JS, Pang NS, Roh BD, et al. (2017) A randomized controlled trial of various MTA materials for partial pulpotomy in permanent teeth. *Journal of Dentistry* 60: 8-13.
 22. Jang Y, Song M, Yoo IS, Song Y, Roh BD, et al. (2015) A Randomized Controlled Study of the Use of ProRoot Mineral Trioxide Aggregate and Endocem as Direct Pulp Capping Materials: 3-month versus 1-year Outcomes. *Journal of endodontics* 41(8): 1201-1206.
 23. Higgins JPT, Altman DG, Gøtzsche PC, Jüni P, Moher D, et al. (2011) The Cochrane Collaboration's tool for assessing risk of bias in randomised trials. *BMJ* 343: d5928-d5928.
 24. Halpern SD, Karlawish JH, Berlin JA (2002) The continuing unethical conduct of underpowered clinical trials. *Jama* 288(3): 358-362.
 25. Mahmoud SH, El-Negoly SA, Zaen El-Din AM, El-Zekrid MH, Grawish LM, et al. (2018) Biodentine versus mineral trioxide aggregate as a direct pulp capping material for human mature permanent teeth - A systematic reviews. *Journal of conservative dentistry* 21(5): 466-473.
 26. Hilton TJ (2009) Keys to clinical success with pulp capping: a review of the literature. *Operative dentistry* 34(5): 615-625.
 27. Bolan M, Rocha M (2007) Histopathologic study of physiological and pathological resorptions in human primary teeth. *Oral surgery, oral medicine, oral pathology, oral radiology, and endodontics* 104: 680-685.
 28. Schwendicke F, Dörfer CE, Paris S (2013) Incomplete Caries Removal: A Systematic Review and Meta-analysis. *Journal of dental research* 92(4): 306-314.
 29. Gupta SK (2011) Intention-to-treat concept: A review. *Perspectives in clinical research* 2(3): 109-112.
 30. Dammaschke T, Leidinger J, Schäfer E (2010) Long-term evaluation of direct pulp capping—treatment outcomes over an average period of 6.1 years. *Clinical oral investigations* 14(5): 559-567.
 31. Ward J (2002) Vital pulp therapy in cariously exposed permanent teeth and its limitations. *Australian Endodontic Journal* 28(1): 29-37.
 32. Min KS, Park HJ, Lee SK, Park SH, Hong CU, et al. (2008) Effect of mineral trioxide aggregate on dentin bridge formation and expression of dentin sialoprotein and heme oxygenase-1 in human dental pulp. *Journal of endodontics* 34(6): 666-670.
 33. Luketić SF, Malčić A, Jukić S, Anić I, Šegović S, et al. (2008) Coronal microleakage of two root-end filling materials

- using a polymicrobial marker. *Journal of endodontics* 34(2): 201-203.
34. Iwamoto CE, Adachi E, Pameijer CH, Barnes D, Romberg EE, et al. (2006) Clinical and histological evaluation of white ProRoot MTA in direct pulp capping. *American journal of dentistry* 19(2): 85.
 35. Camilleri J, Sorrentino F, Damidot D (2013) Investigation of the hydration and bioactivity of radiopacified tricalcium silicate cement, Biodentine and MTA Angelus. *Dental materials* 29(5): 580-593.
 36. Zhou HM, Shen Y, Wang ZJ, Li L, Zheng YF, et al. (2013) In vitro cytotoxicity evaluation of a novel root repair material. *Journal of endodontics* 39 (4):478-483. <https://doi.org/10.1016/j.joen.2012.11.026>
 37. Bertassoni LE, Habelitz S, Kinney J, Marshall SJ, Marshall Jr GW (2009) Biomechanical perspective on the remineralization of dentin. *Caries research* 43(1): 70-77.
 38. Yang B, Flaim G, Dickens SH (2011) Remineralization of human natural caries and artificial caries-like lesions with an experimental whisker-reinforced ART composite. *Acta biomaterialia* 7(5): 2303-2309.
 39. Okiji T, Yoshida K (2009) Reparative dentinogenesis induced by mineral trioxide aggregate: a review from the biological and physicochemical points of view. *International journal of dentistry*.
 40. Mohan N, Nair PD (2008) Polyvinyl alcohol-poly (caprolactone) semi IPN scaffold with implication for cartilage tissue engineering. *Journal of Biomedical Materials Research Part B: Applied Biomaterials: An Official Journal of The Society for Biomaterials, The Japanese Society for Biomaterials, and The Australian Society for Biomaterials and the Korean Society for Biomaterials* 84(2): 584-594.
 41. Ma PX (2008) Biomimetic materials for tissue engineering. *Advanced drug delivery reviews* 60(2): 184-198.
 42. Yazdanfar I, Gutknecht N, Franzen R (2015) Effects of diode laser on direct pulp capping treatment. *Lasers in medical science* 30(4): 1237-1243.
 43. Hasheminia SM, Feizi G, Razavi SM, Feizianfard M, Gutknecht N, et al. (2010) A comparative study of three treatment methods of direct pulp capping in canine teeth of cats: a histologic evaluation. *Lasers in medical science* 25(1): 9.
 44. Olivi G, Genovese MD, Maturo P, Docimo R (2007) Pulp capping: advantages of using laser technology. *European journal of paediatric dentistry* 8(2): 89-95.
 45. Aguilar P, Linsuwanont P (2011) Vital pulp therapy in vital permanent teeth with cariously exposed pulp: a systematic reviews. *Journal of endodontics* 37(5): 581-587.
 46. Ricucci D, Loghin S, Siqueira JF (2014) Correlation between clinical and histologic pulp diagnoses. *Journal of endodontics* 40(12): 1932-1939.
 47. Bogen G, Chandler NP (2010) Pulp preservation in immature permanent teeth. *Endodontic Topics* 23(1): 131-152.
 48. Aminabadi NA, Parto M, Emamverdizadeh P, Jamali Z, Shirazi S (2017) Pulp bleeding color is an indicator of clinical and histohematologic status of primary teeth. *Clinical oral investigations* 21(5): 1843.