



Technical Approach to Aesthetic Improvement in Patients diagnosed Linear nevus sebaceous syndrome, Complex Skin and Ocular Syndromes

Mizzi S*

Senior Maxillofacial Prosthetist and Ocularist, Norfolk and Norwich University Hospital, UK

***Corresponding author:** Miss Samantha Marie Mizzi Bsc (Hons), Senior Maxillofacial Prosthetist and Ocularist, Norfolk and Norwich University Hospital, UK; Email: samantha.mizzi@nnuh.nhs.uk

Received Date: September 04, 2024; **Published Date:** November 11, 2024

Abstract

This case study represents an approach to help improve aesthetics and confidence of a patient who was diagnosed with Linear nevus sebaceous syndrome, SCALP syndrome, congenital melanocytic naevus syndrome, Dermoid affecting both eyes but predominantly the right cornea with a Right temporal arachnoid cyst, no intracranial extension.

Clinical Case

A child patient was presented with Linear nevus sebaceous syndrome, SCALP syndrome, congenital melanocytic nevus syndrome, Dermoid affecting both eyes but predominantly the right cornea with a Right temporal arachnoid cyst, no intracranial extension. Several surgical attempts were made to improve aesthetics to the right side, due to the growing dermoid in the right eye this patient must have a procedure under GA every few years to reduce the dermoid growth. This patient required a right cosmetic shell to improve aesthetics and increase confidence. This study followed the dry pigment with monopoly syrup technique, the material used for making the artificial eye was heat-cured scleral and clear acrylic similar to Pine KR, et al. [1,2].

Treatment Plan

From an ocular prosthetic point of view - I wanted to put into practice a technique of fabricating an artificial eye that I could use to Improve aesthetics and allow the patient to wear the cosmetic shell on top of the growing dermoid in the right eye. This cosmetic shell had to be kept as thin as possible to try and follow a similar aesthetic result to natural left eye.

Method Technical Approach

The 0.6mm cosmetic shell was fabricated using dry pigments and in a traditional way with adjustments to the processes (Figures 1-3).

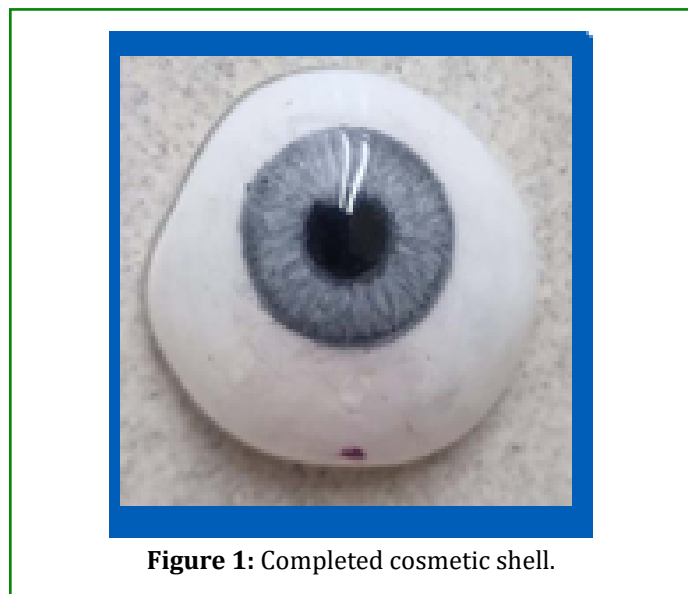


Figure 1: Completed cosmetic shell.



Figure 2: 0.5mm thickness of eye.

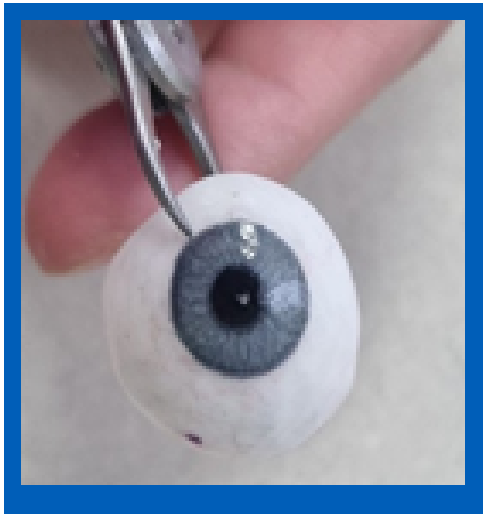

Figure 3: Showing how thin the eye.

The aim of this case study was to see whether I could improve aesthetics by making a thin cosmetic shell 0.6mm thin, whilst also making clearance in the fitting surface of the dermoid growth, this would allow the patient to wear the cosmetic shell alongside their dermoid diagnosis. I did this by making the cosmetic shell following the Moorfield's dry pigment technique however the processed did need to be adjusted due to the thickness of the cosmetic shell there was not enough space for the corner unit to be present, the alternative was to make the sclera shell in acrylic fist, this was used as an alternative to wax molding. I marked the iris position directly onto the sclera shell and painted directly onto the scleral shell (Figure 4). Once the paint was dry, this was processed into clear, and highly polished.

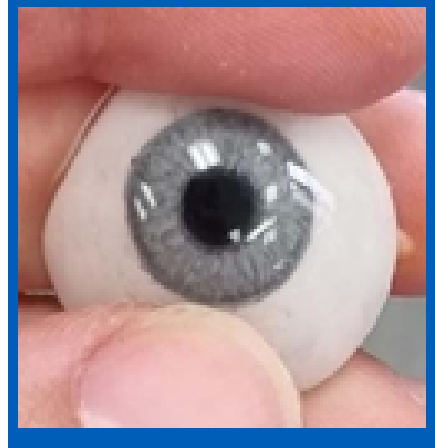


Figure 4: Completed eye colour.

During finishing stage, I trimmed a small amount of the fitting surface away to make room for the growing dermoid, to prevent dry eye syndrome I placed a channel into the fitting surface with a small pin hold to allow for tear exchange to occur and reduce discomfort when wearing the artificial eye (Figure 5).

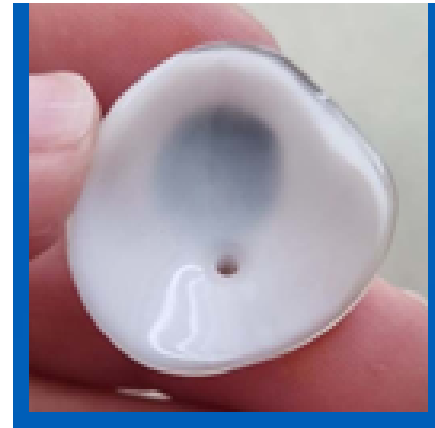


Figure 5: Drainage channel and drainage hole.

Result

Due to the 0.6mm thin shell, minor distortions occurred during the paint drying process in the oven at 60°C this distortion is shown in Figure 6. Capping was also observed when placing it into the mold. To solve this, I would allow the paint to dry naturally at room temperature. Although this would increase processing time slightly, it would prevent distortion of the thin shell in the oven. Despite this minor issue, the cosmetic shell achieved the desired aesthetic results, fitting, and the patient was satisfied with its appearance.




Figure 6: Eye during flasking.

References

1. Pine KR, Sloan BH, Jacobs RJ (2015) Making and fitting prosthetic eyes. *Clinical Ocular Prosthetics*, pp: 65-78.
2. Bankoti P, Singhal MK, Nair C, Chandra P (2016) Characterization of an eye prosthesis using monopoly syrup. *Indian Journal of Dental Research* 27(5): 555-558.